

Foreign Body: An Unreported Association with Mucosectomy Scar

A 44-year-old man with a history of alcohol abuse and smoking was receiving follow-up at our hospital owing to chronic pancreatitis. As he was suffering vague dyspeptic symptoms, he underwent esophagogastroduodenoscopy. The endoscopic examination identified a slightly depressed hyperemic esophageal lesion, 1.5 cm in diameter, 31 cm distal to the superior dental arcade, which did not stain on exposure to Lugol's solution (Figure 1). Histopathological examination of the endoscopic biopsies revealed a superficial squamous-cell carcinoma, with areas of high-grade dysplasia. The integrity of the submucosal layer was confirmed by endoscopic ultrasonography. Endoscopic mucosectomy was carried out as a curative treatment, as described in the recent literature [1], apparently with initial success. Histopathological examination of the tissue removed during the mucosectomy showed that the cancer was restricted to the mucosal layer.

A check-up endoscopy was carried out three months later; the patient was completely asymptomatic. The examination revealed a white, regular scar in the area corresponding to the previous mucosectomy (Figure 2). Biopsies carried out to investigate the scar revealed a foreign body – a piece of cotton thread 15 cm long (Figure 3).

Foreign bodies in the esophagus are a common problem, mainly in children. Adults are less likely to swallow undigestible items deliberately, with the exception of a few groups in which there is clearly a

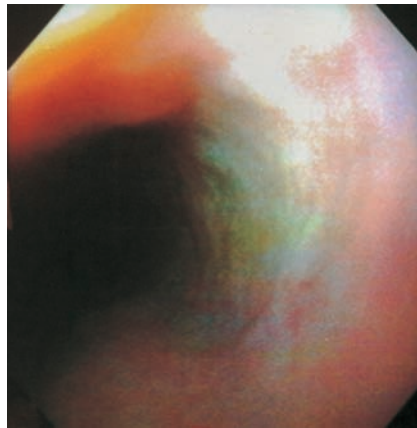


Figure 2 Check-up endoscopy at the site of the previous mucosectomy

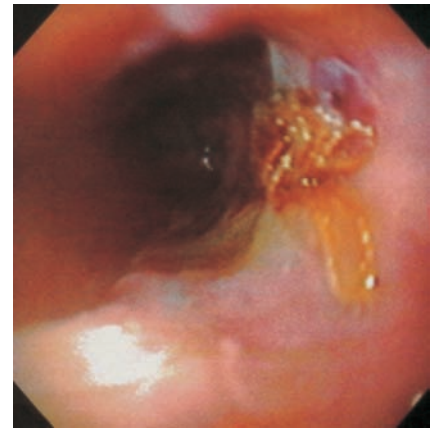


Figure 3 The mucosectomy site after biopsy. Note the cotton thread that was underneath the reepithelialized mucosa

high risk – individuals with psychiatric illness, abusers of drugs or alcohol (as in this patient), and prison inmates. Esophageal impaction occurs more frequently in adults when there is pathological narrowing of the esophagus, as in peptic stricture or distal esophageal ring [2]. Cancer is rarely associated with foreign-body impaction [3]. It has been reported that mucosectomy may be associated with severe complications such as hemorrhage or perforation, in approximately 6.8% of cases. However, a search of the literature failed to identify any previous reports of cases of reepithelialization over a foreign body after mucosectomy.

C. F. G. Viana¹, J. E. Brunaldi²,
J. L. P. Modena²

¹Dept. of Internal Medicine,
Division of Gastroenterology

²Dept. of Surgery and Traumatology,
Digestive Endoscopy Section,
Faculty of Medicine of Ribeirão Preto,
University of São Paulo, Ribeirão Preto,
Brazil

References

- ¹ Lambert R. Endoscopy mucosectomy: an alternative treatment for superficial esophageal cancer. *Recent Results Cancer Res* 2000; 155: 183–192
- ² Yeaton P, Peura DA. Foreign bodies. In: Castell DO, Richter JE (eds). *The esophagus*. Philadelphia: Lippincott-Raven, 1999; 3rd ed.: 335–348
- ³ Nandi P, Ong GB. Foreign body in the oesophagus: review of 2394 cases. *Br J Surg* 1978; 65: 5–9

Corresponding Author

C. F. G. Viana, M.D.

Departamento de Clínica Médica
Hospital das Clínicas
Faculdade de Medicina
Ribeirão Preto-USP
Campus Universitário
14048-900 Ribeirão Preto, SP
Brazil

Fax: + 55-16-633-6695

E-mail: cyntiafgv@usa.net

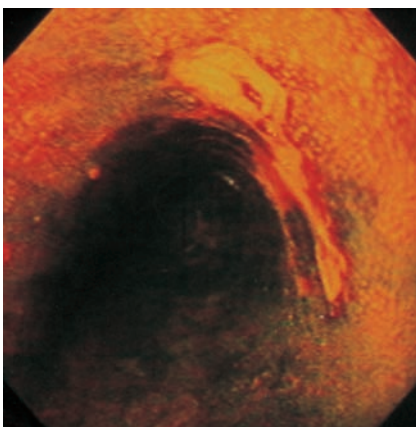


Figure 1 A slightly depressed, hyperemic early esophageal cancer. Lugol staining was negative