

Giant Stone in the Common Bile Duct

A. Okano, H. Takakuwa, A. Nishio

Dept. of Gastroenterology,
Tenri Hospital, Nara, Japan

Corresponding Author

A. Okano, M.D.
Dept. of Gastroenterology
Tenri Hospital
200 Mishima-cho, Tenri
Nara 632-8552
Japan
Fax: + 81-743-62-5576
E-mail: okano-ae@nara-i.net

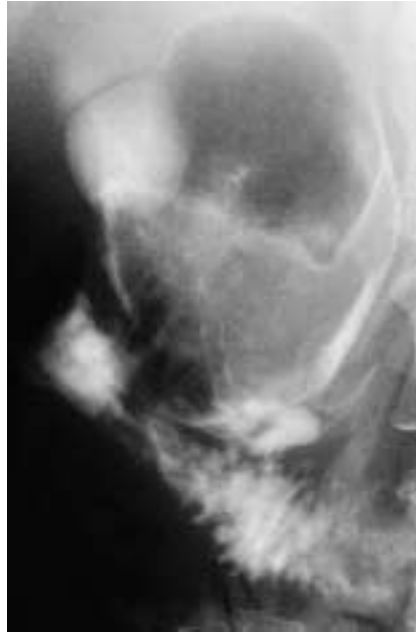


Figure 1 The endoscopic retrograde cholangiogram demonstrated an oval filling defect, 8 × 5 cm in size, in the dilated common bile duct, as well as the dilated cystic duct. The intrahepatic bile ducts and gallbladder were not visualized.

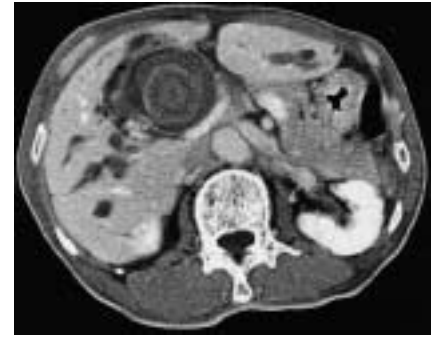

Figure 2 Computed tomography of the abdomen showed a giant, stratified calculus in the common bile duct, as well as the dilated intrahepatic bile ducts. The stone in the common bile duct was measured at 5 × 5 cm. The stone was removed by laparotomy.