

B. Junge<sup>1,2</sup>  
W. Popp<sup>4</sup>  
S. Ruehm<sup>3</sup>  
A. W. Rettenmeier<sup>4</sup>  
U. Dührsen<sup>2</sup>  
M. Rünzi<sup>1,2</sup>

## Fire Eater's Risk: Lipoid Pneumonia Following Aspiration of a Liquid Hydrocarbon Mixture

*Feuerschlucker-Lunge: Lipoidpneumonie nach Aspiration eines Kohlenwasserstoff-Gemisches*

### Zusammenfassung

Die akute Aspiration eines Kohlenwasserstoff-Gemisches kann bei Feuerschluckern eine schwere lipide Pneumonie auslösen. Die Toxizität des aspirierten Gemisches wird bestimmt von der Länge der Kohlenwasserstoffketten und den biophysikalischen Eigenschaften. Wir berichten im Folgenden über einen Patienten mit einer schweren lipiden Pneumonie nach versehentlicher Aspiration einer Kohlenwasserstoff-haltigen Flüssigkeit. Die der Intoxikation zugrunde liegenden Pathomechanismen, der diagnostische Algorithmus und die therapeutische Strategie werden anhand dieses Falles diskutiert.

### Abstract

Acute aspiration of a liquid hydrocarbon mixture by fire eaters may cause severe lipoid pneumonia. The toxic effect of ingested hydrocarbon chains depends on their length and biophysical qualities. We report the case of a patient who accidentally aspirated a hydrocarbon liquid resulting in a lipoid pneumonia. The pathomechanism, diagnostic work-up, and the therapeutic approach are discussed.

### Introduction

Liquid hydrocarbons with a chain length of C 9–C 16 are usually characterized by low oral and dermal toxicity and a relatively high flash point. These qualities are used by fire eaters. Very rarely some of the liquid is aspirated with enormous consequences. We report an incidental aspiration leading to severe lipoid pneumonia.

### Case Report

A 32-year-old healthy student acted as a fire eater and accidentally aspirated some unknown liquids he had used for this purpose. Shortly thereafter he complained about coughing, a burning pharyngeal sensation radiating towards the right shoulder, and

right thoracic pain. Within hours his temperature rose to 38.7 °C, a slight nausea developed and diarrhea.

On admission the male patient (176 cm/62 kg) was in reduced clinical condition. Physical examination of the lungs showed an asymmetric breath excursion of the right side and an elevated right diaphragm. Further examinations were unremarkable. His medical history included an allergic rhinitis and a nicotine consumption of 15 cigarettes per day. Laboratory testing showed an ESR of 26 mm per hour, leucocytes 27 000/ul, CRP 310 mg/l (< 3 mg/l), fibrinogen 727 mg/dl (200–400 mg/dl), and ferritin 490 ng/ml (30–200 ng/ml).

Spirometry revealed a forced vital capacity (FVC max.) of 3.1 l, and a forced expiratory volume in one second, FEV1 of 2.54 l, indicating a mild restrictive impairment. The pO<sub>2</sub> was 66.3 mmHg, the pCO<sub>2</sub> 33.2 mmHg, and the pH value 7.45. The chest radio-

### Institutsangaben

<sup>1</sup>Zentrum für Innere Medizin, Kliniken Essen Süd

<sup>2</sup>Department of Medicine

<sup>3</sup>Radiology

<sup>4</sup>Hygiene und Occupational Medicine, University of Essen

### Korrespondenzadresse

PD Dr. med. M. Rünzi · Zentrum für Innere Medizin · Kliniken Essen Süd · Propsteistraße 2 · 45239 Essen

### Bibliografie

Pneumologie 2002; 56: 547–549 © Georg Thieme Verlag Stuttgart · New York · ISSN 0934-8387

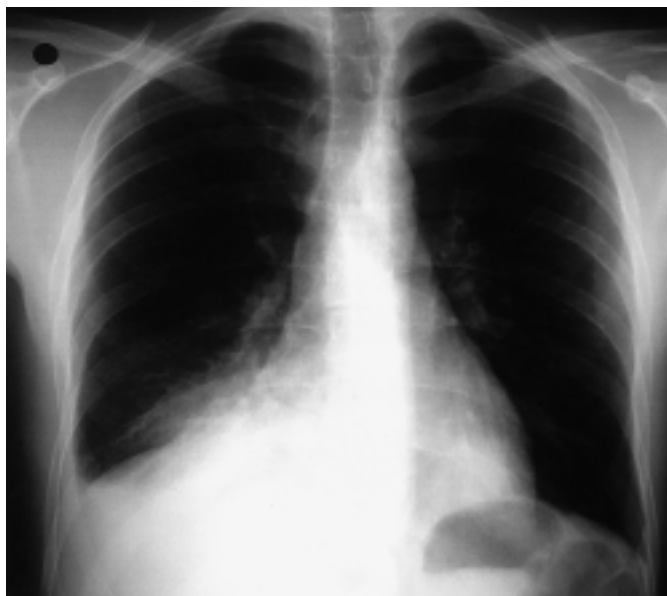

Fig. 1 Posterioranterior chest radiograph shows right middle and lower lobe infiltrates and accompanying ipsilateral effusion caused by accidental aspiration of a liquid hydrocarbon mixture.

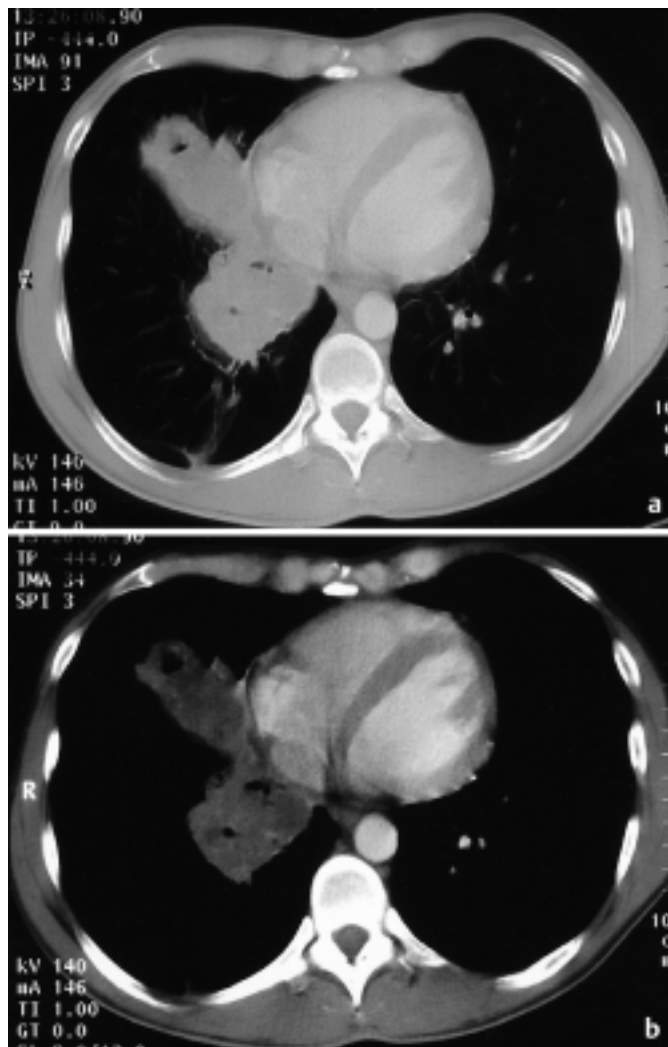


Fig. 2 Corresponding contrast-enhanced chest CT scans, obtained at the same level in Fig. 2a) and b) (Fig. 2a: lung window setting; Fig. 2b: mediastinal window setting), demonstrate the extent of alveolar consolidations in the right middle and lower lobes.

graph showed a pneumonia with infiltration of the right middle and lower lobe and a corresponding pleural effusion (Fig. 1). CT scans depicted expanded infiltrations of the right lung, and the left lower lobe (Fig. 2). Flexible bronchoscopy with bronchoalveolar lavage was unremarkable.

The patient was treated with analgetics (metamizole p.o.), application of  $\beta$ -2-sympathomimetica, topic corticosteroids (budesonide; 2 inhalations every 6 hrs.) and amoxicillin IV (1.2 g, every 8 hrs.). Amoxicillin was given for 9 days and topic corticosteroids were applied for 14 days each.

A distinct relief of symptoms was noticed soon. The inflammatory response decreased. In serial chest radiographs over three weeks a resorption of the pneumonia and the pleural effusion was noticed. On follow-up he was well with normal physical examinations, chest radiograph and laboratory testing.

## Discussion

Mass spectrometric analysis of the aspirated mixture yielded a chain length of C10–C12 with a major part of alkanes and a minor part of alkenes. The mixture was halogen-free.

The toxicity of aliphatic hydrocarbons depends on their length. Alkanes with 3 to 9 carbon atoms mainly exhibit CNS depressive effects such as narcosis and anesthesia. Hexane, pentanes, and heptanes also produce peripheral neuropathy [1]. Typical for the chain length our patient aspirated are a chemical pneumonitis, pulmonary edema and hemorrhage. Acute toxic effects were shown in rats [2]. Immediate death due to respiratory paralysis, asphyxia, and cardiac arrest occurred after the rats had inhaled hydrocarbon with the chain length of C6–C8. Frequently restricted ventilation, disturbances and a partial insufficiency occur [2] as we also noticed.

Flexible bronchoscopy often shows inflammatory signs and edema. The extent of the cellular damage depends not only on the carbon chain length, but also on the biophysical components (i.e., oil bases), as well as on the amount of the aspirated liquid. Hydrocarbons at low surface tension support a quick spreading into the tissue, a low viscosity favours a deep penetration [3,4].

The hydrocarbons our patient aspirated belong to the lipophilic decanes, undecanes, and duodecanes, with low surface tension and viscosity. These qualities of the aspirated mixture destroy the surfactant and result in the damage of the alveolar cell membrane and the pulmonary capillaries [1]. As a consequence, instability of the alveolars with pulmonary edema may occur. A local inflammatory reaction and fibrosis of the tissue follow the edema [3,4]. Alkanes were proved to be well absorbed by human tissue, and may be metabolized in the liver. Furthermore alkanes and alkenes were shown to cause cellular changes in erythrocytes [1]. This explains elevated transaminases as an expression of toxic hepatitis and the possible hemolysis after hydrocarbon intoxication. Presently, studies indicate that none of the alkanes possess teratogenic, mutagenic, or carcinogenic properties [1].

Usually patients involved in an accidental hydrocarbon aspiration experience a complete restitution after some weeks [3,5].

However, complications may develop, i. e. pulmonary abscesses, effusions, bronchopleural fistula formation and a bacterial superinfection [4,6]. Our patient did not suffer any of these complications. His treatment was started with  $\beta$ -2-sympathomimetics, topic corticosteroids and prophylactic antibiotics. Treatment with corticosteroids is controversially discussed [3,7,8]. Experimental studies could not provide a reliable effect [2]. Nevertheless, a favourable course of patients treated with corticosteroids is reported [3,7–10]. Prophylactic antibiotics seem to be of benefit since fever and an elevated leucocyte count can occur, and may also indicate a bacterial pneumonia as differential diagnosis [8,11].

Exogenous lipid pneumonia has traditionally been considered a chronic process secondary to continued aspiration or inhalation of fatty substances. For example, it has been shown as accidental aspiration to vaseline for placing of nasogastric tubes or nasal drops, or laxatives based on oil [5,10]. The chronic process is difficult to diagnose and should be remembered when a patient presents with unspecific nodular pulmonary changes on chest radiographic examination.

In summary, exogenous lipid pneumonia is a rare but severe disease with a course which may be underestimated and requires focussed as well as prophylactic treatment to achieve a potentially good prognosis.

## References

- 1 Sandmeyer E. Aliphatic hydrocarbons. In: Patty's Industrial Hygiene and Toxicology. New York: George D Clayton, Florence E Clayton, 1981: 3175–3199
- 2 Mullin LS, Ader AW, Daughtrey E et al. Toxicology update: Isoparaffinic hydrocarbons – a summary of toxicity studies and human exposure data. *J Appl Toxicol* 1990; 10: 135–142
- 3 Hoppe U, Pothoff G, La Roseé K et al. Toxische Kohlenwasserstoffpneumonie bei einem Feuerschlucker. *Med Klin* 1995; 90: 263–266
- 4 Groß MW, Hess HU, Parasirin-Bauer A et al. Lungenabszesse bei Feuerschluckern – Radiologische Befunde. *Rofo Fortschr Geb Rontgenstr Neuen Bildgeb Verfahr* 1995; 162: 183–185
- 5 Beermann B, Christensson T, Möller P et al. Lipoid pneumonia: an occupational hazard of fire eaters. *B Med J* 1984; 289: 1728–1729
- 6 Franquet T, Gómez-Santos D, Giménez A et al. Fire eater's pneumonia: Radiographic and CT findings. *J Comput Assist Tomogr* 2000; 24: 448–450
- 7 Ewert R, Lindemann I, Romberg B et al. Akzidentelle Aspiration und Ingestion von Petroleum bei einem Feuerschlucker. *Dtsch Med Wschr* 1992; 117: 1594–1598
- 8 Truemper E, de la Rocha SR, Atkinson SD. Chemical characteristics pathophysiology, and management of hydrocarbon ingestion: case report and review of the literature. *Pediat Emerg Care* 1987; 3: 187–193
- 9 Lores L, Ribas J, Ruiz J et al. Acute lipid pneumonia. Report of 2 cases. *Med Clin (Barc.)* 1996; 106: 747–748
- 10 Bernabeu Mora R, Mendez Martinez P, Abellan Martinez MC et al. Acute lipid pneumonia by accidental aspiration of vaseline used in nasogastric intubation. *Arch Broncopneumol* 2000; 36: 485–487
- 11 Brander PE, Taskinen E, Stenius-Aarniala. Fire-eater's lung. *Eur Respir J* 1992; 5: 112–114