

W. Bohle, W. G. Zoller

Department of Gastroenterology,
Katharinenhospital Stuttgart, Stuttgart,
Germany

Corresponding Author

W. Bohle, M.D.

Department of Gastroenterology
Katharinenhospital Stuttgart
Kriegsbergstrasse 60
70174 Stuttgart
Germany

Fax: +49-711-2785401

E-mail: W.Bohle@katharinenhospital.de

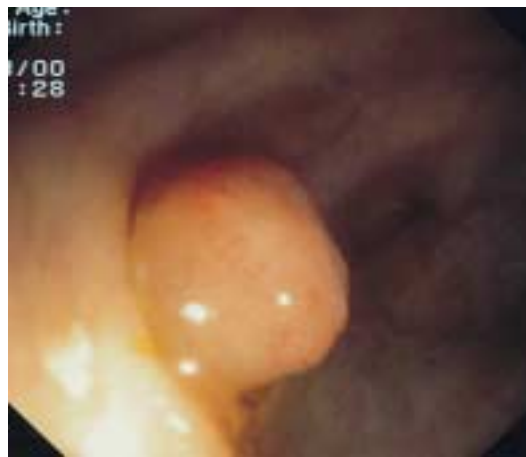

Figure 1 An 81-year-old man presenting with general weakness and anemia, underwent colonoscopy because of a positive hemocult test. During the examination, several small, sometimes centrally eroded polyps, measuring 6–8 mm in diameter, were found.

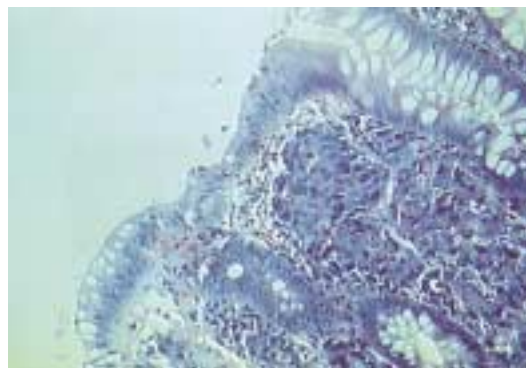


Figure 2 Histological analysis revealed submucosal metastatic spread of an adenocarcinoma, incompletely covered by normal mucosa. Gastroscopy revealed an adeno-squamous carcinoma of the esophagogastric junction to be the primary tumor. The patient refused further treatment and died several weeks later.