

S. Vernace¹, C. Maltz²

Division of Gastroenterology and Hepatic Diseases, Weill Cornell Medical School, New York, USA

Corresponding Author

C. Maltz, MD, PhD

520 East 70th St.
New York
NY 10021
USA
Fax: +1-212-746-4734
E-mail: cmaltz@pol.net

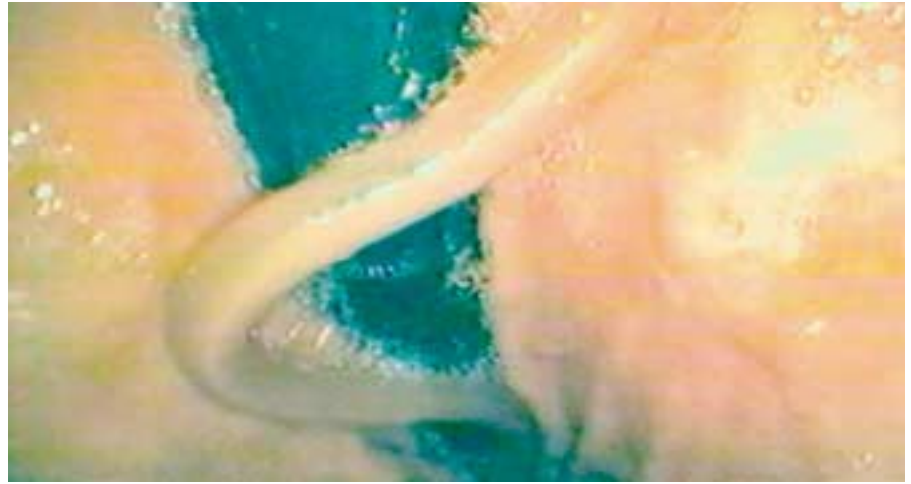


Figure 1 An 81-year-old Chinese-born man, with a history of lung cancer for which he had received both radiation and chemotherapy, underwent upper endoscopy for odynophagia. When the stomach was entered, a motile tubular structure with tapered ends and approximately 6 mm diameter and 20 cm length was noted. This had the appearance of *Ascaris lumbricoides*. The patient was treated with one dose of albendazole without effect on his symptoms.