

Capsule endoscopy was recently introduced for endoluminal visualization of the small bowel [1]. The clinical utility of the procedure is undisputed [2–4], and for most patients, swallowing the capsule (11 × 33 mm in size) does not pose any problems. However, use of the capsule in small children has not yet been reported.

A 3-year-old boy was admitted to our hospital with chronic iron-deficiency anemia and tarry stools. The hemoglobin level had ranged from 3.4 to 10.3 over a 2-year period, despite continuous iron replacement therapy. Upper and lower endoscopy, computed tomography of the abdomen, Meckel scintigraphy, and a small-bowel follow-through had all been unremarkable.

Capsule endoscopy was carried out with the patient under general anesthesia. The capsule was grasped in a polypectomy snare through the endoscope and pushed through the upper esophageal sphincter. The capsule was placed in the duodenal bulb, to avoid the risk of gastric retention of a capsule this size. After 54 min (approximately 30 min after release), a large polypoid tumor without ongoing bleeding was clearly visualized (Figure 1). The rest of the small bowel was normal, with passage of the cecum after a total time of 4 min 50 s.

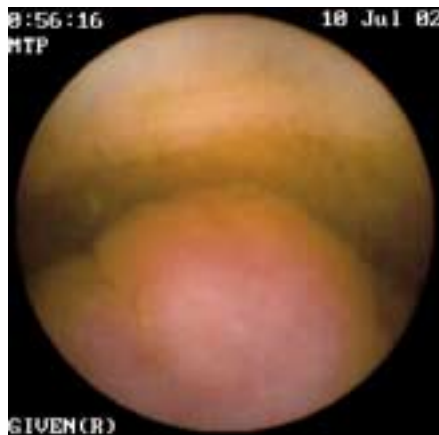


Figure 1 Capsule image showing a polypoid lesion in the jejunum, causing partial obstruction of the lumen.

Based on the capsule endoscopy finding, a minilaparotomy was performed, and a tumor 17 × 15 mm in size was found and resected in the suspected part of the jejunum, 100 cm from the ligament of Treitz (Figure 2). Histology showed that the lesion consisted of hamartomatous tissue, without no sign of malignancy. The post-operative course was uneventful, with no recurrence of anemia.

This case illustrates the feasibility of capsule endoscopy even in small children, using an endoscope to insert the capsule. It also shows the low sensitivity of small-bowel follow-through studies in detecting small to moderate-sized tumors in the small bowel.

**L. Aabakken¹, T. Scholz²,
A. B. Østensen³, R. Emblem²,
T. Jermstad¹**

¹ Dept. of Medical Gastroenterology, Rikshospitalet University Hospital, Oslo, Norway

² Dept. of Pediatric Surgery, Rikshospitalet University Hospital, Oslo, Norway

³ Dept. of Pediatrics, Rikshospitalet University Hospital, Oslo, Norway.

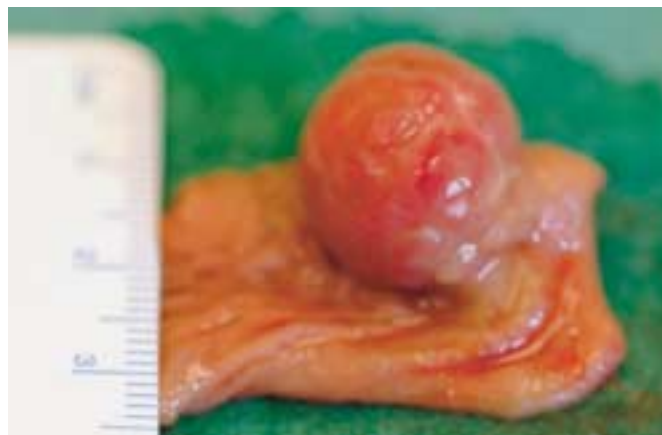

Figure 2 The resected specimen, a 17 × 15 mm hamartomatous polyp.

References

- ¹ Gavriel Iddan G, Meron G, Glukhovsky A et al. Wireless capsule endoscopy. *Nature* 2000; 405: 417
- ² Ell C, Remke S, May A. The first prospective controlled trial comparing wireless capsule endoscopy with push enteroscopy in chronic gastrointestinal bleeding. *Endoscopy* 2002; 34: 685–689
- ³ Lewis BS. Enteroscopy: endangered by the capsule? *Endoscopy* 2002; 34: 416–417
- ⁴ Lewis BS, Swain P. Capsule endoscopy in the evaluation of patients with suspected small intestinal bleeding: results of a pilot study. *Gastrointest Endosc* 2002; 56: 452–456

Corresponding Author

L. Aabakken, M. D.

Dept. of Medical Gastroenterology
Rikshospitalet University Hospital
0027 Oslo
Norway

Fax: +47-2307-2008

E-mail: larsaa@klinmed.uio.no