

Percutaneous transhepatic biliary drainage (PTBD) is an established means of treating biliary disease after endoscopic retrograde cholangiopancreatography (ERCP) has failed [1]. Arterial bleeding from a PTBD tract is very uncommon as a late complication [2,3] – in contrast to the early phase after PTBD placement, during which this may rarely occur [4–6]. We present here the case of a 74-year-old man with a 2-year history of malignant biliary stricture (Bismuth IV) who received treatment with a unilateral 16-Fr Yamakawa-type prosthesis to drain the right lobe of the liver. More than a year after the creation of the tract and after several uneventful exchanges of the Yamakawa-type prosthesis, the patient presented prior to schedule because of fever and an inability to flush the prosthesis. He also reported melena. Laboratory investigations showed an alkaline phosphatase level of 1291 U/l (normal range 60–180), γ -glutamyltransferase 394 U/l (normal range <28), bilirubin 13.7 mg/dl (normal range <1.2), and C-reactive protein 7.9 mg/dl (normal range <0.5); leukocytes were normal.

On exchanging the drain, blood coagula were seen protruding from the PTBD even during insertion of the guide wire. After removal of the prosthesis, spurting arterial bleeding occurred. Initially, an 18-Fr Nimura prosthesis without side holes was placed to stop the bleeding mechanically by compression. Abdominal computed tomography revealed the known large tumor in the area of the liver hilum. Where the drain crossed the right hepatic artery, a sudden decrease in the caliber of the artery was seen, suggesting tumor erosion. On subsequent angiography, after removal of the drain (again resulting in spurting bleeding), contrast leakage from the artery into the PTBD tract was demonstrated (Figure 1,2). After failure to insert a covered metallic stent to seal the leak (prevented by an anatomic variant), microcoils were placed by means of angiography (Figure 3), leading to sufficient vascular blockade on both sides of

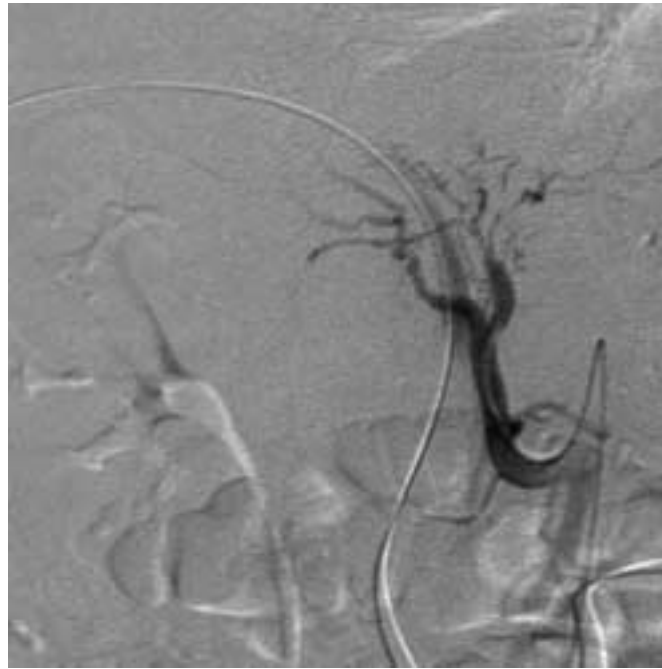


Figure 1 Digital subtraction angiography, showing contrast extravasation at the crossing of the artery and the percutaneous transhepatic biliary drainage tract.

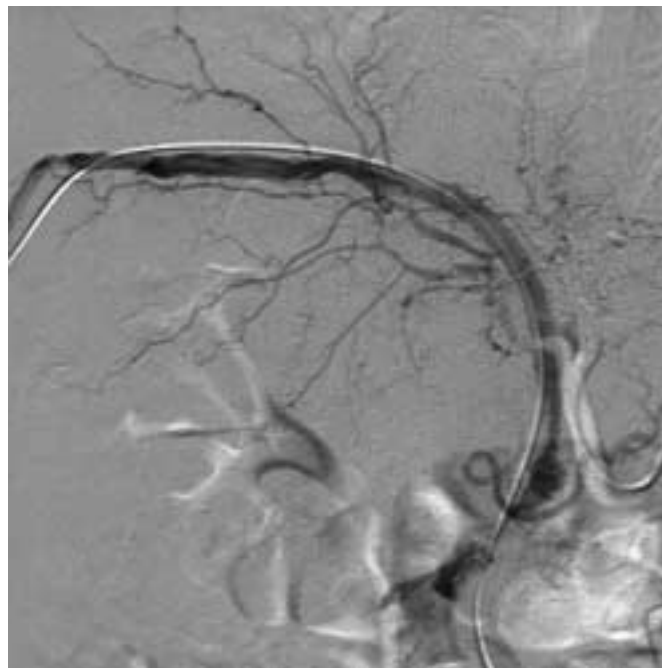


Figure 2 Digital subtraction angiography. The strength of the bleeding was indicated by rapid contrast filling of the whole biliary tract.

the leak. Removal of the PTBD after this was not associated with any further signs of rebleeding. After the patient had been discharged with a Yamakawa-type prosthesis, there were no further bleeding epi-

sodes during a follow-up period of 3 months. Embolization of the artery did not cause any obvious problems, although the patient's general condition progressively deteriorated.

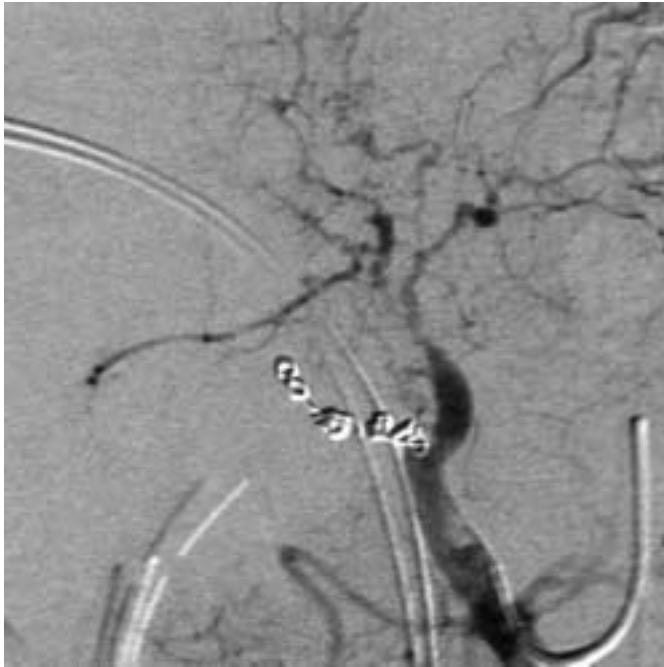

Figure 3 Successful implantation of microcoils.

Corresponding Author

P. Born, M.D.

II. Medizinische Klinik,
Klinikum rechts der Isar
Technische Universität München
Ismaningerstrasse 22
81675 München
Germany
Fax: +49-89-4140-4905
E-mail: Peter.Born@lrz.tum.de

In conclusion, this case demonstrates that a serious bleeding complication can occur even more than 1 year after PTBD placement. The treatment is by angiography, similar to the management of early PTBD-related bleeding complications. In this context, it is of little importance whether the erosion was due to the tumor (as we believe in this case) or to the prosthesis itself.

**P. Born¹, T. Rösch¹, W. Sandschin¹,
W. Weiss²**

¹ Dept. of Internal Medicine II

² Institute of Radiology, Technical University of Munich, Klinikum rechts der Isar, Munich, Germany.

References

- ¹ Shah SK, Mutignani M, Costamagna G. Therapeutic biliary endoscopy. *Endoscopy* 2002; 34: 43–53
- ² Born P, Rösch T, Triptrap E et al. Long-term results of percutaneous transhepatic biliary drainage for benign and malignant bile duct strictures. *Scand J Gastroenterol* 1998; 33: 544–549
- ³ Schumacher B, Othman T, Jansen Met al. Long-term follow up of percutaneous transhepatic therapy (PTT) in patients with definite benign anastomotic strictures after hepaticojejunostomy. *Endoscopy* 2001; 33: 409–415
- ⁴ L'Hermine C, Ernst O, Delemazure O, Sergent B. Arterial complications of percutaneous transhepatic biliary drainage. *Cardiovasc Intervent Radiol* 1996; 19: 160–164
- ⁵ Bülau S, Berger H, Dittler H et al. Arrest of PTCD-induced hemorrhage using a covered metal stent. *Endoscopy* 2000; 32: 57
- ⁶ Born P, Golder W, Allescher H et al. Severe arterial bleeding after percutaneous transhepatic cholangiographic drainage. *Endoscopy* 1995; 27: 343