

Angiolipoma of the Duodenum Diagnosed After Endoscopic Resection

UCTN

A 60-year-old woman was referred to our hospital because of dyspepsia of 6 months' duration. Endoscopy revealed a long tubular-shaped polypoid lesion measuring 3.5 cm in length located in the duodenal bulb covered by smooth yellowish-pink mucosa (Figure 1). Endoscopic ultrasonography (EUS) revealed a hyperechoic lesion with internal anechoic densities in the submucosal layer. The lesion was thought to be an unusual type of lipoma, and duodenal polypectomy was done. Gross examination of the resected specimen showed an elongated tubular-shaped mass, 0.4 × 3.5 cm, covered with normal mucosa. Histopathological examination revealed a tumor which had arisen in the submucosa, composed of mature adipose tissue and small vessels with fibrin thrombi within the vascular channels (Figure 2). The entire tumor had been successfully removed. The patient was discharged 3 days later and remains completely asymptomatic. Angiolipoma is a rare benign soft tissue tumor, an unusual variant of lipoma, consisting of fatty and vascular components and located in the subcutaneous tissue, usually of the trunk and extremities [1]. Histologically, these neoplasms consist of mature adipose tissue interspersed with capillaries with notable pericytic proliferation. They have a prominent vascular component comprising

of numerous small capillaries that are dilated or filled with fibrin thrombi. Angiolipoma of the GI is rare [2,3], especially in the small bowel. Only one case of angiolipoma of the small bowel has been reported [4]. The tumor is usually asymptomatic, but may present with abdominal pain, obstruction, intussusception and bleeding [2]. Endoscopically, it may be difficult to distinguish angiolipoma from lipoma. Both appear as smooth, rounded tumors that are usually sessile, but can be pedunculated as in this case. In order to make the differential diagnosis we carried out EUS. The characteristic EUS finding for lipoma is of a hyperechoic mass located in the submucosa. However, in this case, EUS revealed a hyperechoic lesion with an internal anechoic echo texture in the submucosa. Although there is controversy about how angiolipoma should be treated, we carried out an endoscopic resection for accurate diagnosis and treatment.

I. S. Jung, J. Y. Jang, C. B. Ryu, S. J. Hong, J. O. Kim, J. Y. Cho, J. S. Lee, M. S. Lee, S. Y. Jin, C. S. Shim, B. S. Kim
Institute for Digestive Research,
Soon Chun Hyang University,
College of Medicine Seoul, Korea.

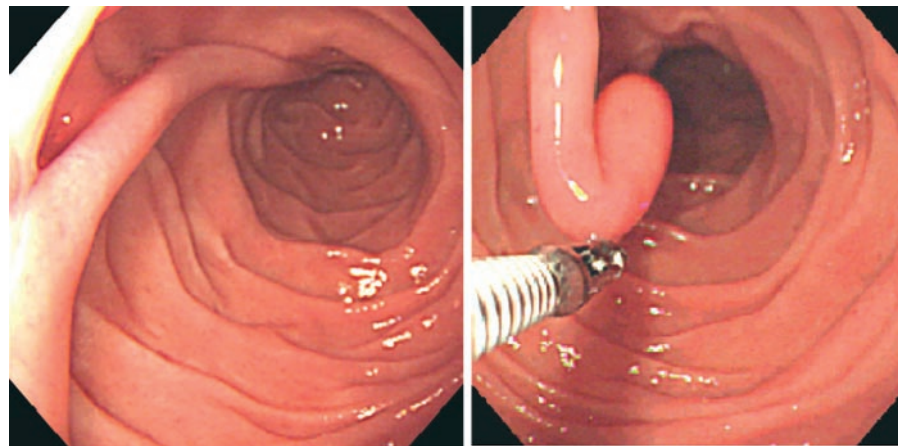


Figure 1 Endoscopy revealed a yellowish-pink long tubular-shaped polypoid lesion about 3.5 cm in length with a smooth surface, in the duodenal bulb.

References

- 1 Provencale JM, McLendon RE. Spinal angiolipomas: MR features. *AJNR Am J Neuroradiol* 1996; 17: 713–719
- 2 DeRidder PH, Levin AJ, Katta JJ, Catto JA. Angiolipoma of the stomach as a cause of chronic upper gastrointestinal bleeding. *Surg Endosc* 1989; 3: 106–108
- 3 Hunt J, Tindal D. Solitary gastric Peutz-Jeghers polyp and angiolipoma presenting as acute haemorrhage. *Aust NZ J Surg* 1996; 66: 713–715
- 4 Kaneko T, Karasawa Y, Inada H, Tamura Y et al. An adult case of intussusception due to inverted Meckel's diverticulum accompanied by angiolipoma. *Nippon Shokakibyo Gakkai Zasshi* 1996; 4: 260–265

Corresponding Author

C. S. Shim, M. D.

College of Medicine
Soon Chun Hyang University Hospital
657 Hannam-Dong, Youngsan-Ku
Seoul 140-743
Korea
Fax: +82-2-7491968
E-mail: jisdr@medimail.co.kr

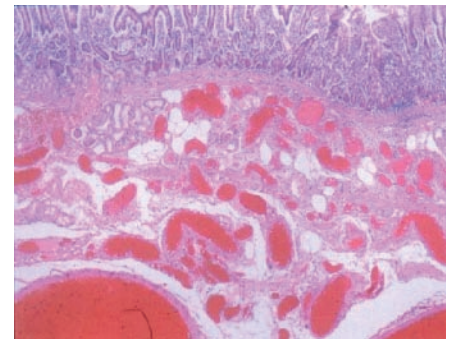


Figure 2 Histopathological examination of the lesion revealed a tumor which had arisen in the submucosa composed of mature adipose tissue and small vessels with fibrin thrombi within the vascular channels.