

First described in 1980, percutaneous gastrostomy is now established as a safe and useful means of providing enteral nutrition. The working lifespan of a gastrostomy varies from weeks to many months and a significant proportion of patients will require replacement of the tube at least once, and occasionally several times [1,2].

Replacement of the tube is technically simple in most patients, involving the introduction of a new, lubricated tube through the existing stoma. However, we have found it difficult to replace tubes in some patients for one or more of the following reasons: a) narrowing of the tract, either due to fibrosis or to voluntary muscle spasm in apprehensive patients; b) the oblique course of some tracts; and c) the relative flexibility of the tubes, which leads to bending of the tube instead of forward movement into the tract when force is applied (Figure 1).

We found that by reinforcing the soft tube we could carry out replacement in all these situations. The reinforcement technique consists of passing an endoscopic biopsy forceps through the tube, making sure that the tip of the forceps reaches at least to the tip of the gastrostomy tube (Figure 2). The forceps may protrude just outside the tip of the gastrostomy tube, but this is not essential. The forceps affords just enough firmness, while retaining some flexibility, to facilitate insertion of the tube without creating false tracts. After the tube has been advanced into the stomach to a satisfactory extent, the biopsy forceps is removed and the gastrostomy tube is fixed.

Passing the tube over a guide wire or freezing of the gastrostomy tube in order to stiffen it are other alternatives, but we find that the biopsy forceps stylet technique is by far the simplest and most successful method.

**S. Kumar, J. S. Dreyer**

Department of Surgery, Dumfries and Galloway Royal Infirmary, Dumfries, UK.

### References

- <sup>1</sup> Koulentaki M, Reynolds N, Steinke Det al. Eight years' experience of gastrostomy tube management. *Endoscopy* 2002; 34: 941–946
- <sup>2</sup> Sartori S, Trevisani L, Nielsen Iet al. Longevity of silicone and polyurethane catheters in long-term enteral feeding via percutaneous endoscopic gastrostomy. *Aliment Pharmacol Ther* 2003; 17: 853–856

### Corresponding Author

**S. Kumar**

Department of Surgery  
Dumfries and Galloway Royal Infirmary  
C6 Maryfield Terrace  
Glencaple Road  
Dumfries  
DG1 4UG  
UK

Fax: +44-1387-241088

E-mail: sanskriti@hotmail.com

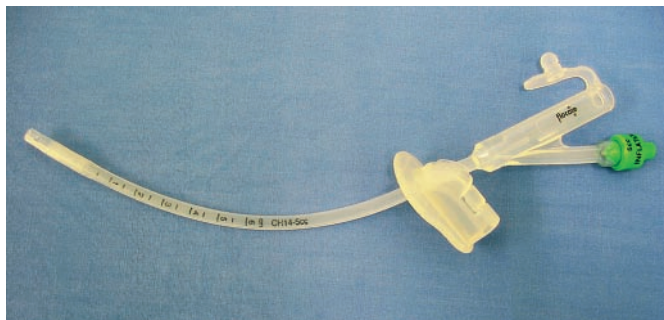

Figure 1 A gastrostomy tube on its own is quite flexible.

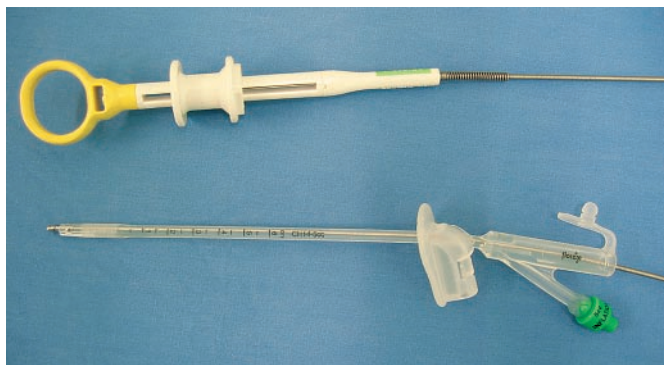


Figure 2 Reinforcement of a gastrostomy tube with an endoscopic biopsy forceps makes it more rigid.