

# Treatment of Multiple Rectal Carcinoids by Endoscopic Mucosal Resection Using a Device for Esophageal Variceal Ligation

# UCTN

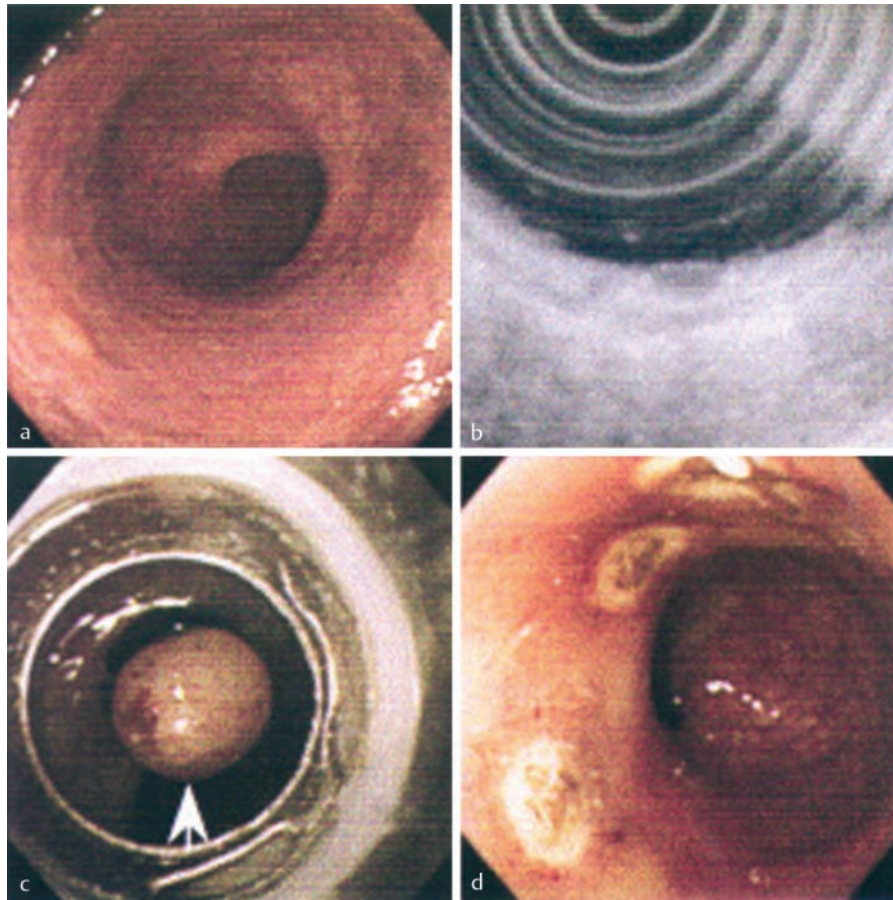


Figure 1 Rectal carcinoid tumors. **a** Endoscopic appearance before resection. **b** Endoscopic ultrasonogram before resection. **c** Mucosal resection of a carcinoid nodule (arrow) using an esophageal variceal ligation device. **d** Endoscopic view after resection.

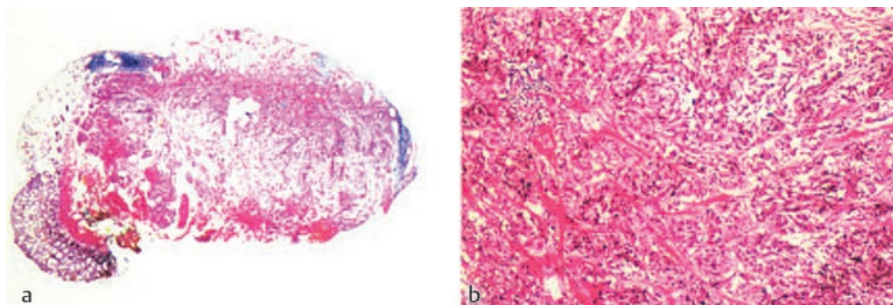


Figure 2 Histological appearance (**a**  $\times 20$ , **b**  $\times 100$ ) of carcinoid tumor infiltrating the submucosal layer. The resection margins were free of tumor.

A 54-year-old man was referred to our hospital because of lower abdominal discomfort. Total colonoscopic examination was performed and four protruding yellow-white lesions, 6 mm or less in diameter, were detected in the rectum (Figure 1a). At endoscopy it was suspected that these lesions were rectal carcinoids and this diagnosis was confirmed by histological examination of biopsy specimens. Endoscopic ultrasonography demonstrated that the carcinoid tumors were localized within the submucosal layer (Figure 1b). Abdominal ultrasonography and computed tomography did not show any evidence of abdominal lymph node swelling or of metastatic lesions in the liver.

Repeat endoscopy was performed for endoscopic mucosal resection of the rectal carcinoid nodules. The usual endoscopic mucosal resection technique was used to resect the 6-mm nodule, after lifting the mucosa by injecting hypertonic saline-epinephrine (50  $\mu\text{g}/\text{ml}$ ) into the submucosa adjacent to the tumor. To resect the other three nodules, for each of them, the mucosa was first lifted by submucosal injection of hypertonic saline-epinephrine, the elevated mucosa, containing the small nodule was ligated using an esophageal variceal ligation device and resected using an endoscopic snare device (Figures 1c and 1d). Histological examination showed rectal carcinoids with a "festoons and ribbons" pattern, with clear resection margins (Figure 2).

Rectal carcinoids are relatively uncommon lesions, representing only 1.3% of all rectal tumors [1]. They usually present as small solitary nodules and multicentricity is rare, occurring in only a few percent of cases [2,3]. The present treatment guidelines for rectal carcinoids are controversial, but seem to be based on tumor size and depth of invasion. Most would agree that small lesions of less than 10 mm can be adequately treated by endoscopic resection or local excision [2–4]. The band ligation method has been applied to treat

early esophageal, gastric, and colonic neoplasms. Using this method, we achieved complete local resection of multiple rectal carcinoids. Previous studies suggest that complete local resection of carcinoid tumor is associated with a low rate of local recurrence [2,5]. This method seems to be useful for the resection of small carcinoid tumors of the rectum.

**Y. Okamoto<sup>1</sup>, M. Fujii<sup>1</sup>, S. Tateiwa<sup>1</sup>, T. Sakai<sup>1</sup>, F. Ochi<sup>1</sup>, M. Sugano<sup>1</sup>, K. Oshiro<sup>1</sup>, K. Masai<sup>2</sup>, Y. Okabayashi<sup>1</sup>**

<sup>1</sup> Department of Internal Medicine, Kobe Red Cross Hospital (formerly Suma Red Cross Hospital), Kobe, Japan

<sup>2</sup> Clinical Laboratory Unit, Kobe Red Cross Hospital (formerly Suma Red Cross Hospital), Kobe, Japan.

## References

- <sup>1</sup> Godwin JDII. Carcinoid tumors: an analysis of 2837 cases. *Cancer* 1975; 36: 560–569
- <sup>2</sup> Jetmore AB, Ray JE, Gathright JB Jret al. Rectal carcinoids: the most frequent carcinoid tumor. *Dis Colon Rectum* 1992; 35: 717–725
- <sup>3</sup> Mani S, Modlin IM, Ballantyne G et al. Carcinoids of the rectum. *J Am Coll Surg* 1994; 179: 261–278
- <sup>4</sup> Naunheim KS, Zeitels J, Kaplan EL et al. Rectal carcinoid tumors – treatment and prognosis. *Surgery* 1983; 94: 670–676
- <sup>5</sup> Sauven P, Ridge JA, Quan SH et al. Anorectal carcinoid tumors. Is aggressive surgery warranted? *Ann Surg* 1990; 211: 67–71

## Corresponding Author

**M. Fujii, M.D.**

Department of Internal Medicine  
Kobe Red Cross Hospital (formerly  
Suma Red Cross Hospital)  
Wakinohama-Kaigandori  
Chuo-ku  
Kobe 650-0073  
Japan  
Fax: +81-78-241-7053  
E-mail: fuji.ma@dream.com