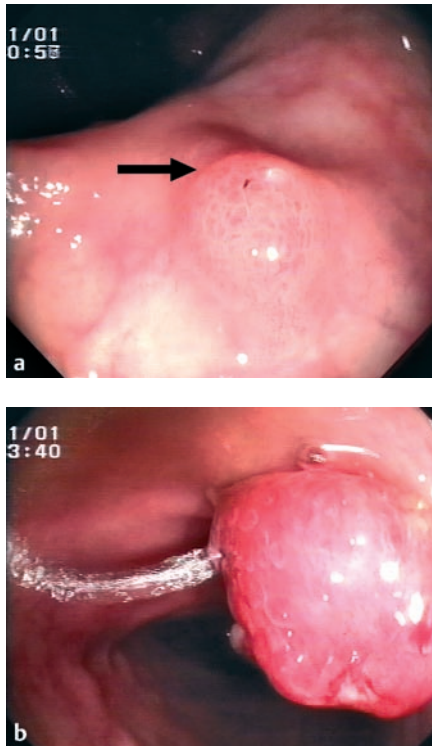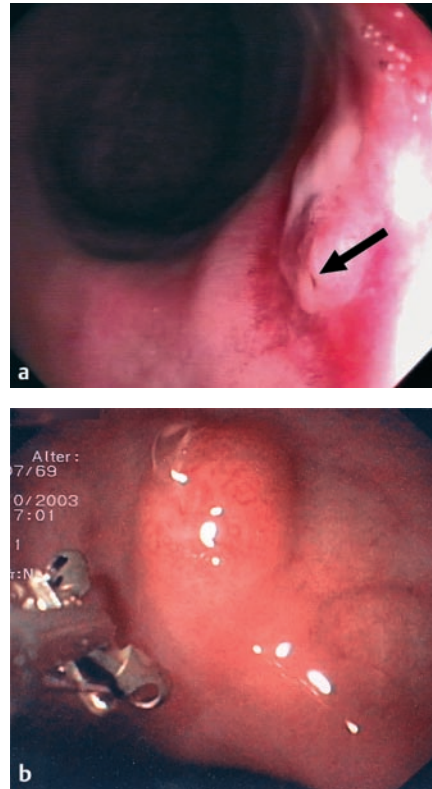


**Figure 1** **a** Intact right ureterosigmoidostomy with notable submucosal tunnelling of the ureter (arrow). **b** Granulomatous polyp at the left stoma site with stream of urine.

Ureterosigmoidostomy is the oldest and simplest form of continent urinary diversion. Although first described by Simon in 1852 [1], the procedure was not widely accepted until Coffey introduced submucosal tunnelling of the ureters in 1911 [2]. The procedure fell into disfavor with Hammer's report of the first case of carcinoma at the ureterocolic junction [3] and with the introduction of the ileal conduit. The basic carcinogenic mechanism at the anastomotic mucosa is the interaction of urine and feces [4]; the theory involves bacterial production of nitrosamines from nitrates and endogenous amines [5].

We present a case of endoscopic removal of a benign polyp at the site of a ureterosigmoidostomy in a 32-year-old man who was born with hypospadias and bladder exstrophy. At the age of 3 months he had undergone cystectomy with submucosal reimplantation of both ureters into the



**Figure 2** **a** The functionally intact left ureterosigmoid stoma with fibrinous erosions and visible ostium (arrow) 10 weeks after polypectomy. **b** Appearance of normal stoma 20 months later.

sigmoid wall. At 20 years he had developed mucosal carcinoma at the left ureteral ostium and segmental sigmoid resection was done with an antireflux re-insertion of both ureters. He presented 12 years later with anemia and a history of loss of blood per anum. Colonoscopy disclosed a tumor at the left ureteral stoma (Figure 1). Histological examination revealed a benign granulomatous polyp. However, after endoscopic snare polypectomy, the patient developed severe pain in his left side and fever, and ultrasound showed a dilated left renal pelvis. Percutaneous nephrostomy was necessary for 10 weeks. Thereafter, the stomal edema lessened and we found a functionally intact ostium (Figure 2a). After a follow up of 23 months the patient felt well, and he had no residual tumor or loss of function related to the ureterosigmoidostomy (Figure 2b).

As well as its screening and diagnostic uses, endoscopy has a therapeutic role in selected patients with ureterosigmoidostomy.

**M. Kleemann<sup>1</sup>, A. Müldner<sup>2</sup>, J. Weiss<sup>3</sup>, B. C. Manegold<sup>2</sup>**

<sup>1</sup> Department of Surgery, University Hospital of Schleswig-Holstein–Campus Lübeck, Lübeck, Germany

<sup>2</sup> Department of Surgical Endoscopy, University Hospital Mannheim, Mannheim, Germany

<sup>3</sup> Department of Urology, University Hospital Mannheim, Mannheim, Germany.

## References

- Simon J. Operation for directing the orifices of ureters into the rectum; temporary success, subsequent failure; autopsy. *Lancet* 1852; 2: 568–570
- Coffey RC. Physiologic implantation of the severed ureter or common bile duct into the intestine. *JAMA* 1911; 56: 397–403
- Hammer E. Cancer du colon sigmoïde dix ans pres implantation des ureters d'une vessie extrophie. *J Urol* 1929; 28: 260–263
- Azimuddin K, Khubchandani I, Stasik J et al. Neoplasia after ureterosigmoidostomy. *Dis Colon Rectum* 1999; 42: 1632–1638
- Husman DA, Spence HM. Current status of tumor of the bowel following ureterosigmoidostomy: a review. *J Urol* 1990; 144: 607–610

## Corresponding Author

**M. Kleemann, M.D.**

Department of Surgery,  
University Hospital Schleswig-Holstein –  
Campus Lübeck  
Ratzeburger Allee 160  
23538 Lübeck  
Germany

Fax: +49-451-5002069

E-mail: markus.kleemann@chirurgie.mu-luebeck.de