

We have encountered a number of difficulties when using the cap method for endoscopic mucosal resection (EMR) procedures. First, we had to use a specially designed crescent snare to perform the pre-looping maneuver to place the snare around the inner rim of the cap, which sometimes proved awkward. Secondly, suction of the bleb before closing the snare blocked the view of the site and it was difficult to ensure that the snare wire was closed around the middle part of the mucosal bleb. Thirdly, the size of the resected specimen was limited to the diameter of the cap and if we had used a larger cap we would have lost the advantages gained by using a small-diameter endoscope. Finally, when EMR is performed in the esophagus or colon the cap lies parallel to the mucosa, which makes suction difficult unless the

tip of the endoscope is bent by about 90° [1–5]. Faced with these challenges, we designed a new device which consists of a transparent plastic capsule with an oval slit. This is connected to the tip of the endoscope by a rubber sleeve, which allows the capsule to slide over the tip while suction is maintained (Figure 1). When performing EMR using this device, the endoscope is inserted with the capsule in the backward position until the area of mucosa to be resected is reached. The capsule is then pushed forward with the plastic injection tube and the endoscope is rotated until the slit faces the target area. Saline is then injected and the bleb that has been created will be visible inside the capsule. A regular snare wire is then inserted and after suction is applied the snare is closed around the middle part of the bleb (Fig-

ure 2). The whole of this process can be observed because the bleb does not block the endoscopist's view during suction. To resect larger specimens we increased the length of the capsule and the slit without increasing the cap diameter. We resected 29 specimens in animal models (pigs) using this technique and when we used a 11 mm × 21 mm capsule the average diameter of the resected specimens was 18 mm. Another advantage of this technique is that the capsule makes it easier to retrieve the resected specimen.

F. S. Salameh

Department of Surgery 1, Tokyo Medical and Dental University, Tokyo, Japan.

References

- 1 Inoue H, Takeshita K, Hori H et al. Endoscopic mucosal resection with a cap-fitted panendoscope for esophageal, stomach, and colon mucosal lesions. *Gastrointest Endosc* 1993; 39: 58–62
- 2 Tada M, Inoue H, Endo M. Colonic mucosal resection using a transparent cap-fitted endoscope. *Gastrointest Endosc* 1996; 44: 63–65
- 3 Inoue H, Tani M, Nagai K et al. Treatment of esophageal and gastric tumors. *Endoscopy* 1999; 31: 47–55
- 4 Shim C-S. Endoscopic mucosal resection: an overview of the value of the different techniques. *Endoscopy* 2001; 33: 271–275
- 5 Ohkuwa M, Hosokawa K, Boku N et al. New endoscopic treatment for intramucosal gastric tumors using an insulated-tip diathermic knife. *Endoscopy* 2001; 33: 221–226

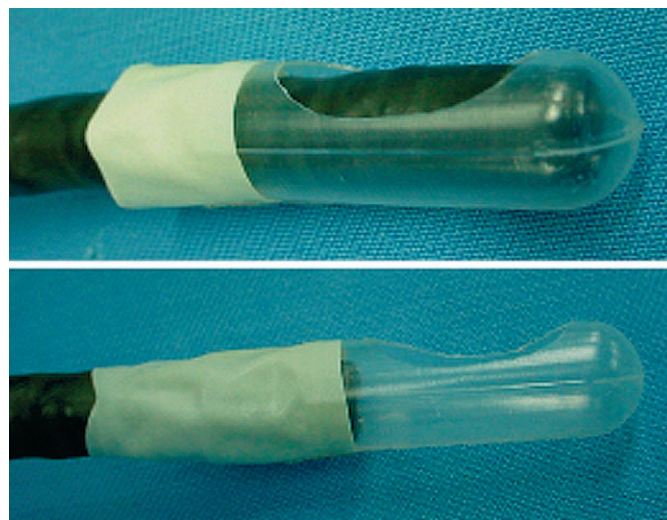


Figure 1 Endoscopic mucosal resection (EMR) capsule in: **a** backward, and **b** forward positions.

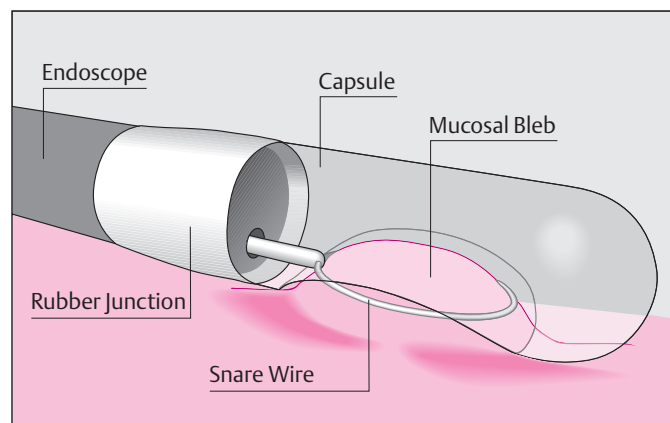


Figure 2 EMR using the capsule technique.

Corresponding Author

F. S. Salameh, MD

Department of Surgery 1
Tokyo Medical and Dental University
Yushima 1-5-45, Bunkyo-Ku 1138519
Tokyo, Japan
Fax: +81-3-38174126
E-mail: salameh.srg1@tmd.ac.jp