

The “Frost Sign”: an Inadvertent Minor Complication of Endoscopic Mucosal Resection

N. Suzuki¹, I. C. Talbot², B. P. Saunders¹

¹ Wolfson Unit for Endoscopy, St. Mark's Hospital, Harrow, United Kingdom

² Dept. of Histopathology, St. Mark's Hospital, Harrow, United Kingdom

Corresponding Author

N. Suzuki, M.D.

Wolfson Unit for Endoscopy
St. Mark's Hospital
Watford Road
Harrow HA1 3UJ
United Kingdom

Fax: +44-20-8234-3588

E-mail: n.suzuki@imperial.ac.uk

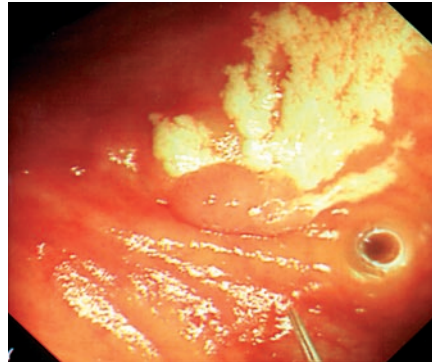


Figure 1 A 72-year-old woman with diarrhoea attended for colonoscopy. An 8-mm sessile polyp was found in her caecum. During submucosal injection to lift the polyp, an unusual white appearance was observed, which we have termed the “frost sign”. On checking the equipment, it was found that air had remained within the injection catheter due to insufficient flushing.

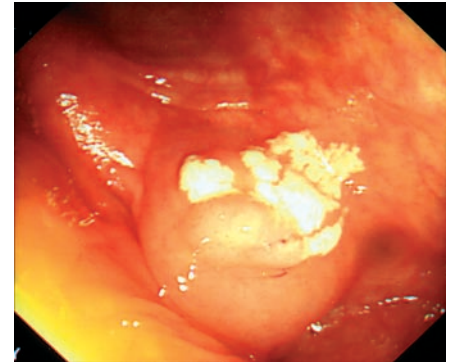


Figure 2 After the needle had been flushed and reinserted, proper mucosal lifting was achieved and the polyp was removed uneventfully.

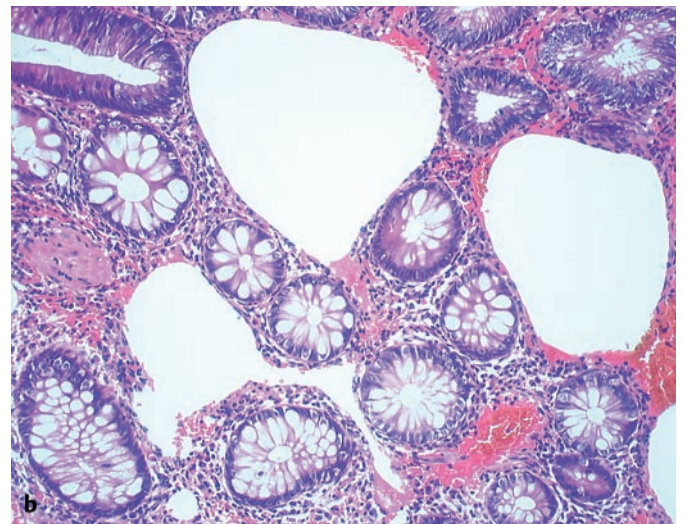
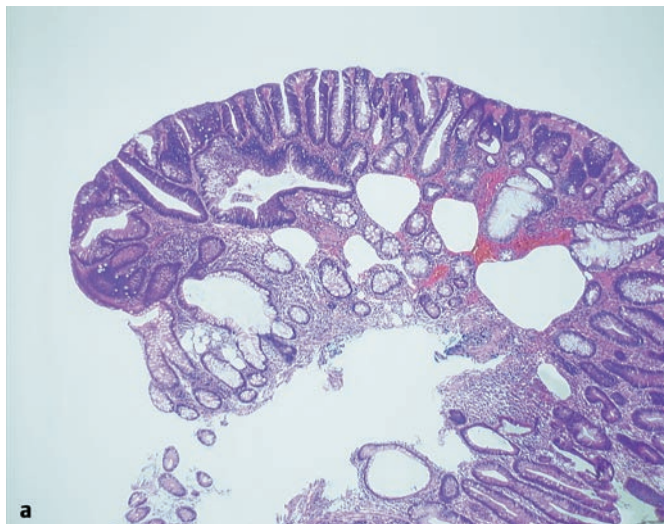


Figure 3 a,b Histological appearance of air bubbles injected into the mucosal layer. The bubbles have dissected the loose connective tissue in the mucosal layer. As an endoscopic injection needle has 2 ml of dead

space, endoscopists and assistants need to ensure that the needle is adequately flushed through in order to prevent inadvertent air injection.