

Biliothoracic fistulas, including bilioleural and biliobronchial fistulas, are rare complications of biliary tract diseases. Bilioleural fistulas have been reported after percutaneous transhepatic procedures such as percutaneous transhepatic drainage (PTD) [1,2] and liver biopsy [3]. Prolonged external biliary drainage with formation of a fistulous tract, and catheter dysfunction by either blockage or by dislocation, should predispose to a bilioleural communication. Percutaneous transhepatic cholangioscopy (PTC) is most frequently carried out in patients with biliary lithiasis [4]. It requires the creation of a transhepatic tract by progressive dilation and maturation for a period of about 2 weeks. Although both conditions for the development of a bilioleural fistula are present, i.e. biliary obstruction and a prolonged biliary drainage period, the development of pleurobililia has not previously been reported.

A 48-year-old patient had been admitted on several occasions because of choledocholithiasis complicated by cholangitis. In February 1997, PTC was performed to remove an impacted stone in the right hepatic duct. At 3 months later, he was readmitted because of jaundice, fever, dyspnea, and right scapular pain. Chest radiography demonstrated a right pleural effusion. A drainage tube was inserted into the right pleural space, and yielded 700 ml of a bile-stained fluid. Blood and pleural cultures grew *Escherichia coli*. Endoscopic retrograde cholangiopancreatography (ERCP) showed bile duct stones; most of them were removed endoscopically. Opacification of the intrahepatic ducts showed a fistula between the right hepatic duct and the right pleural cavity (Figure 1). A nasobiliary catheter was inserted into the right hepatic duct. At a repeat ERCP procedure, performed 5 days later, the fistula could no longer be visualized. The patient recovered uneventfully and was discharged 26 days after admission.

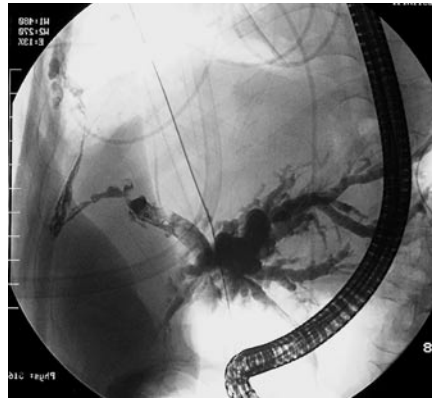


Figure 1 Notice the presence of a fistulous tract (arrowheads) between the right hepatic duct and the right pleural space.

In this patient, a bilioleural communication was detected 3 months after PTC, during which complete clearance of the bile duct had been obtained. Common bile stones, leading to recurrent biliary obstruction, were noticed again shortly after the procedure. Probably, the path created by the large drainage tubes served as an ideal passage through which bile could leak back into the pleural cavity in the presence of persistent biliary tract obstruction. Moreover, suppurative complications in the bile ducts and in the liver may have contributed to the development of the bilioleural fistula. The early institution of another means of effective biliary drainage, either by endoscopic or percutaneous biliary drainage, is the most important factor in the successful management of this complication [2, 5].

X. De Meester¹, D. Vanbeckevoort², R. Aerts³, W. Van Steenberghe¹

¹ Department of Internal Medicine, Unit for Liver, Biliary and Pancreatic Diseases, University Hospital Gasthuisberg, Catholic University of Leuven, Belgium

² Department of Radiology, University Hospital Gasthuisberg, Catholic University of Leuven, Belgium

³ Department of Abdominal Surgery, University Hospital Gasthuisberg, Catholic University of Leuven, Belgium.

References

- ¹ Carrasco CH, Zornoza J, Bechtel WJ. Malignant biliary obstruction: complications of percutaneous biliary drainage. *Radiology* 1984; 152: 343–346
- ² Strange C, Allen ML, Freedland PNet al. Bilioleural fistula as a complication of percutaneous biliary drainage: experimental evidence for pleural inflammation. *Am Rev Resp Dis* 1988; 137: 959–961
- ³ Pisani RJ, Zeller FA. Bilius pleural effusion following liver biopsy. *Chest* 1990; 98: 1535–1537
- ⁴ Van Steenberghe W, Van Aken L, Van Beckevoort Det al. Percutaneous transhepatic cholangioscopy for diagnosis and therapy of biliary diseases in older patients. *J Am Geriatr Soc* 1996; 44: 1384–1387
- ⁵ Brem H, Gibbons GD, Cobb Get al. The use of endoscopy to treat bronchobiliary fistula caused by choledocholithiasis. *Gastroenterology* 1990; 98: 490–492

Corresponding Author

W. Van Steenberghe, MD, PhD

Department of Internal Medicine,
Hepatology Unit
University Hospital Gasthuisberg
Herestraat 49
3000 Leuven
Belgium

Fax: +32-16-344387

E-mail: Werner.vansteenbergen@uz.kuleuven.ac.be