

An 82-year-old man was referred to our hospital with an expanding liver cyst that was compressing the inferior vena cava. His medical history revealed hypertension, chronic obstructive pulmonary disease (COPD), a hip prosthesis, and surgery for varices. At the referring hospital the patient had been treated endoscopically for upper gastrointestinal bleeding by circumferential adrenaline injection of a duodenal ulcer with adherent clot, using a 4 mm long and 0.2 mm thick needle, following which the bleeding stopped.

Abdominal ultrasonography had been performed because physical examination showed an enlarged liver and the patient had developed peripheral edema suggesting inferior vena cava compression. Ultrasound revealed multiple liver cysts, one of which, originating from segment five of the liver, had rapidly increased in size. A contrast-enhanced CT scan had shown a thickened wall with contrast enhancement and gas formation within the cyst (Fig. 1), suspicious for an infected cyst. The cyst compressed the duodenum, and inferior vena cava. The patient's condition

deteriorated and therefore he was referred to our hospital.

The diagnosis of infected liver cyst was confirmed and the cyst was drained percutaneously. Culture of the cyst content showed *Streptococcus viridans*, *Escherichia coli* and *Bacteroides fragilis*. Following drainage, the patient was transferred back to the ward and initially his clinical condition improved and temperature dropped. Unfortunately, the drain accidentally dislocated and fell out, following which the patient developed peritonitis and septic shock. He was taken to the operating theatre for emergency treatment and the diagnosis of infected liver cyst with the duodenum adherent to the medial cyst boundary was confirmed. During the surgical procedure the patient unfortunately went into irreversible septic shock and died 10 days after treatment of his upper gastrointestinal bleeding.

We hypothesize that the cyst became infected by transmural translocation of endoluminal bacteria into the cyst by accidental puncture during adrenaline injection of the bleeding ulcer.

Endoscopic adrenaline injection is an accepted treatment option for upper gastrointestinal bleeding [1–3]. We are unaware of any previous reports of infected liver cysts as a complication of this treatment.

Endoscopists using injection therapy should be aware of complications caused by the needle's passage through the gastrointestinal wall.

**J.-P. Rutten¹, F. Wolters²,
R. van Schelven³, C. H. C. Dejong¹**

¹ Department of Surgery, Academic Hospital Maastricht, Maastricht, The Netherlands

² Department of Gastroenterology and Hepatology, Academic Hospital Maastricht, Maastricht, The Netherlands

³ Department of Internal Medicine, Laurentius Hospital, Roermond, The Netherlands.

References

- 1 Cook DJ, Guyatt GH, Salena BJ, Laine LA. Endoscopic therapy for acute upper gastrointestinal hemorrhage: a meta-analysis. *Gastroenterology*. 1992; 102: 139–144
- 2 Chung SC. Current management of acute gastrointestinal bleeding. *Scand J Gastroenterol* 2003; Suppl (237): 9–12
- 3 Lin HJ, Hsieh YH, Tseng GY et al. A prospective, randomised trial of large- versus small-volume endoscopic injection of epinephrine for peptic ulcer bleeding. *Gastrointest Endosc* 2002; 55: 615–619

Corresponding Author

J.-P. Rutten, M.D.
Department of Surgery
PO Box 5800
6202 AZ Maastricht
The Netherlands
Fax: +31-43-3875473
E-mail: JRUT@surgery.azm.nl

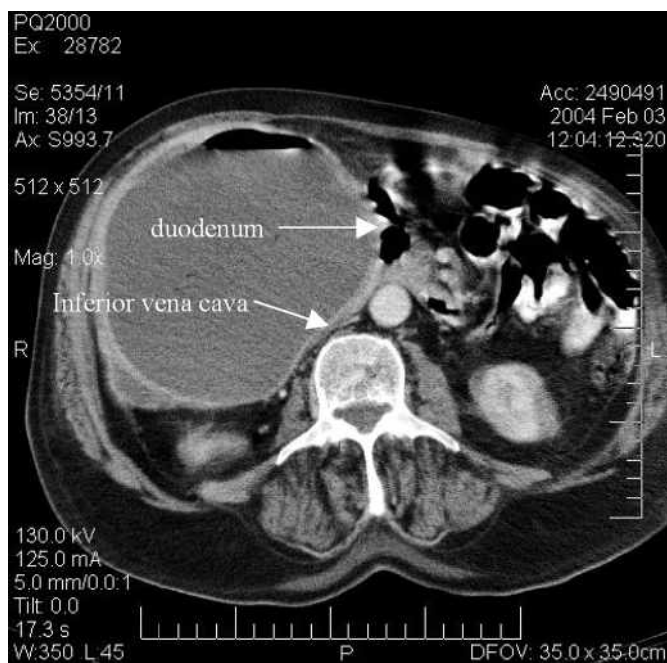


Figure 1 Contrast-enhanced computer tomography (CT) scan showing a huge cyst in segment five of the liver with a thickened wall showing contrast enhancement and gas formation within the cyst. The cyst is compressing the duodenum and the inferior vena cava.