Purulent Pericarditis: a Complication of Endoscopic Oesophageal Variceal Sclerotherapy

A 63-year-old woman with portal hypertension secondary to alcoholic cirrhosis underwent oesophageal variceal sclerotherapy with 5% ethanolamine oleate. She developed prolonged retrosternal pleuritic chest pain, with dyspnoea. Clinical examination revealed tachypnoea, tachycardia, and crepitations at the left lung base. Arterial blood gas analysis showed hypoxia of 7.7 mm Hg (normal range 11.1 – 14.4 mm Hg), but the chest radiograph and electrocardiogram were normal. Since the D-dimer level was raised, a computed tomography (CT) pulmonary angiogram was carried out, which was negative for pulmonary embolism but showed pericardial and pleural effusions (Figure **1**). The patient developed septicaemia with a temperature, tachycardia and hypotension, and had a raised white cell count and C-reactive protein level. Antibiotic treatment was started. She then developed signs of pericardial tamponade, with a raised jugulovenous pulse and muffled heart sounds. An echocardiogram showed a pericardial effusion 3.4 cm in size, with no features of tamponade. A therapeutic pericardiocentesis revealed purulent fluid, which grew coliform bacilli and *Bacteroides* species. A Gastrografin swallow on day 9 was normal. The patient underwent anterior thoracotomy with pericardiectomy, and made a slow but complete recovery.

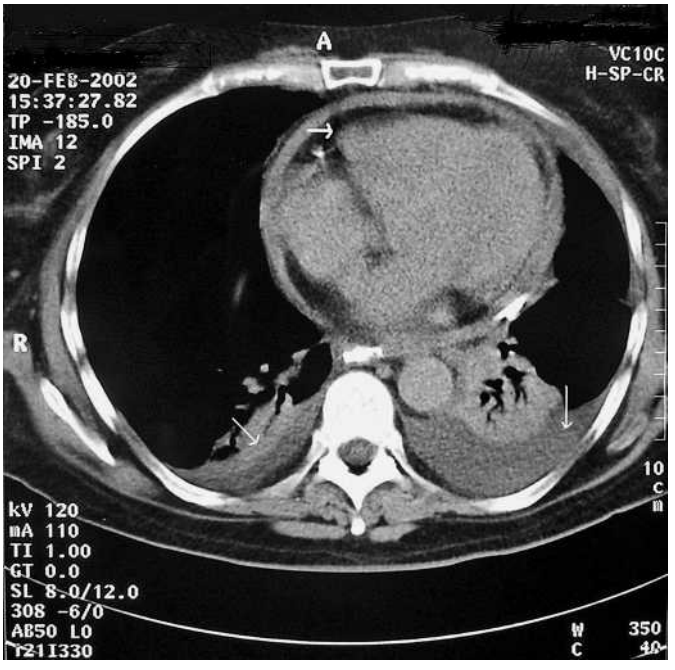

Figure **1** Computed tomogram of the chest, showing pericardial effusion (thick arrow) and bilateral pleural effusions (thin arrows), with basal atelectasis on the left side.

There have been case reports of cardiac tamponade [1,2] and mediastinal abscess [3] after variceal injection sclerotherapy, but not of patients requiring pericardiectomy in this situation. Autopsy studies have shown an incidence of oesophageal perforation of 2.9% [4]. This patient probably suffered an oesophageal perforation into the pericardial cavity due to a extravariceal injection of sclerosant, which formed a microabscess, resulting in purulent pericarditis. This was also the reason for the disparity between the clinical and echocardiographic features. Endoscopic variceal ligation is now the most effective treatment for oesophageal varices (91%; 95% confidence interval, 82.4 – 96.3%) in comparison to injection sclerotherapy (81.1%; 95% CI, 71.1 – 88.4%) [5]. Oesophageal perforation resulting in purulent pericarditis is a potentially life-threatening complication after variceal sclerotherapy. Patients with prolonged chest pain following the procedure should be monitored for complications.

S. Gupta, K. Thompson, L. Grellier
Dept. of Gastroenterology,
Worthing Hospital, Worthing,
West Sussex, United Kingdom.

References

1 Knaeur CM, Fogel MR. Pericarditis – complication of esophageal sclerotherapy: a report of three cases. Gastroenterology 1987; 93: 287 – 290
2 Lam CS, Szeto ML. A rare complication of esophageal sclerotherapy. Hong Kong Med J 1997; 3: 101 – 103
3 Althoff M, Schoenemann J, Weinhold ST et al. Mediastinal abscess following sclerotherapy of esophageal varices. Endoscopy 1995; 27: 630
4 Korula J, Pandya K, Yamada S. Perforation of esophagus after endoscopic variceal sclerotherapy: incidence and clues to pathogenesis. Dig Dis Sci 1989; 34: 324 – 329
5 Seewald S, Mendoza G, Seitz U et al. Variceal bleeding and portal hypertension: has there been progress in the last 12 months? Endoscopy 2003; 35: 136 – 144

Corresponding Author

S. Gupta, M.D.

56 Sunningdale Road
Sutton SM1 2JS
United Kingdom
Fax: +44-208-7253520
E-mail: san1gupta@hotmail.com

This document was downloaded for personal use only. Unauthorized distribution is strictly prohibited.