

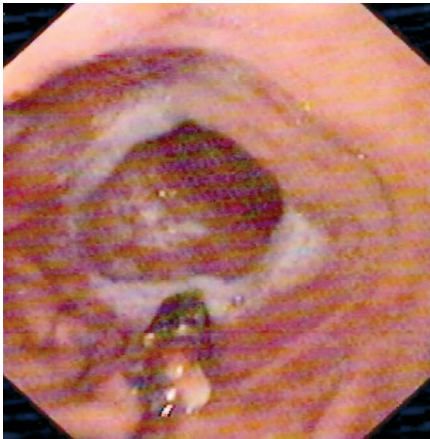Figure 1 The wireless pH capsule attached to the gastric mucosa.

Intra-gastric pH monitoring is an important tool for assessing the pharmacodynamic profiles of antise-cretory agents [1].

Ambulatory 24-hour intra-gastric pH monitoring is usually done by means of an antimony or glass electrode that is placed transnasally. Limitations of catheter-based pH monitoring include discomfort, inconvenience, and interference with normal activity for patients. In addition, precise placement of the pH electrode is crucial for the method, with manometry being required to locate the position of the lower esophageal sphincter [2].

The Medtronic Bravo pH Monitoring System (Medtronic, Vadodara, Gujarat) is a new US Food and Drug Administration (FDA) class 1-approved catheter-free esophageal pH monitoring system that involves the attachment of a radio telemetry capsule to the mucosal wall [3]. There are no published data on the use of the new Bravo system for intra-gastric pH monitoring. We hereby report on the safety, performance, and tolerability of this wireless recording system for intra-gastric pH when the capsule is implanted under endoscopic guidance.

A 26-year-old asymptomatic healthy male volunteer was enrolled. The capsule delivery system was passed orally under

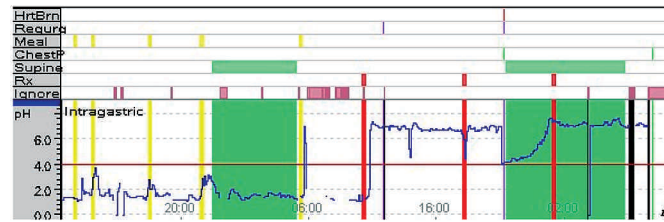


Figure 2 Intra-gastric pH tracing over 48 hours.

endoscopic guidance, with the patient in the left lateral decubitus position. The gastroesophageal junction was first located by endoscopy and then the delivery system was advanced under direct vision so that the pH electrode was at the greater curvature about 10 cm below the squamocolumnar junction. The capsule was then secured to the gastric mucosa following the standard instructions in the user manual (Figure 1).

A 24-hr baseline pH was recorded as the volunteer continued his regular activities. He fasted for the next 24 hours and intravenous rabeprazole given according to the study protocol. On completion of recording, the data were uploaded to a computer via datalink (Medtronic) and a summary of the pH data was generated (Figure 2).

This endoscopy-assisted wireless ambulatory pH recording system appears to be a well-tolerated, reliable means of monitoring intra-gastric pH. The endoscopic visualization ensures uniform and accurate positioning and avoids local trauma during placement. The mucosal attachment of the electrode virtually eliminates the possibility of recording artifacts related to relative movement between the pH electrode and the mucosa during the monitoring period. This refinement in methodology will permit broader use of intra-gastric pH monitoring.

**R. Banerjee, S. Lakhtakia, M. Tandon, G. V. Rao, D. N. Reddy**

Department of Gastroenterology,  
Asian Institute of Gastroenterology,  
Hyderabad, India

## References

- <sup>1</sup> Katz PO. Ambulatory intra-gastric pH monitoring: clinical laboratory to clinical practice. *Rev Gastroenterol Disord* 2003; 3 Suppl 4: S3–S9
- <sup>2</sup> Armstrong D, Bair D, James Cet al. Oral esomeprazole vs. intravenous pantoprazole: a comparison of the effect on intra-gastric pH in healthy subjects. *Aliment Pharmacol Ther* 2003; 18: 705–711
- <sup>3</sup> Pandolfino JE, Richter JE, Ours Tet al. Ambulatory esophageal pH monitoring using a wireless system. *Am J Gastroenterol* 2003; 98: 740–749

## Corresponding Author

**D. N. Reddy, M. D.**

Department of Gastroenterology  
Asian Institute Of Gastroenterology  
6-3-661 Somajiguda  
Hyderabad 500 082  
India

Fax: +91-40-23324255

E-mail: aigindia@yahoo.co.in