

Intussusception of the Appendix Resected at Colonoscopy

UCTN

Intussusception of the appendix is an uncommon condition, and the diagnosis is rarely made preoperatively, although the condition may be suspected on the basis of radiological studies and colonoscopy [1]. Colonoscopy may in fact be the procedure of choice for both diagnosis and for selecting the appropriate course of management [2]. We report a case in which an intussusception of the appendix was resected colonoscopically.

A 41-year-old woman presented with a 4-day history of rectal tenesmus, diarrhea, and recurrent severe paroxysmal abdominal pain. Colonoscopy examination revealed an intussusception of the appendix (Figure 1). In this case a colonoscopic appendectomy was performed successfully with the use of an endoloop ligating system (MAJ-254, HX-20L/Q/U-1; Olympus, Hamburg, Germany). The endoloop was attached over the appendix and then an appendectomy was successfully performed with a polypectomy snare wire (Figure 2). The pathology report confirmed the diagnosis of intussusception of the appendix and the patient made a satisfactory recovery without complications. Colonoscopy should therefore be considered as an excellent choice of treatment in such cases and should be remembered as a second option in patients in whom laparoscopic treatment fails to lead to resolution of the condition.

Endoscopy_UCTN_Code_CPL_1AJ_2AI

A. de Hoyos¹, M. A. Monroy¹, C. Gallegos², G. Checa³

¹ Department of Gastroenterology, Hospital Angeles del Pedregal, Mexico City, Mexico

² Department of Pathology, Hospital Angeles del Pedregal, Mexico City, Mexico

³ Department of Anesthesiology, Hospital Angeles del Pedregal, Mexico City, Mexico.

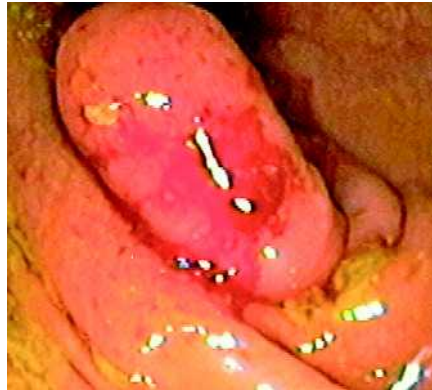

Figure 1 Colonoscopic view showing an intussusception of the appendix.

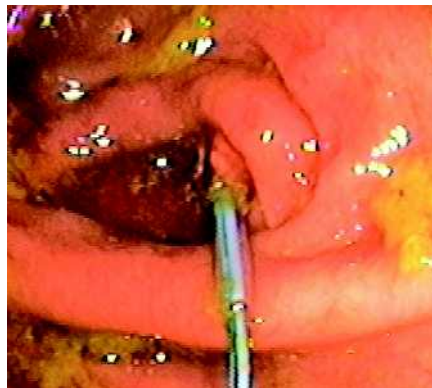


Figure 2 The intussusception was resected endoscopically using an endoloop, seen here over the cecum after the appendectomy.

References

- ¹ Casteels M, Eggermont E, Kerremans R et al. Intussusception of the vermiform appendix: a preoperative diagnosis in an adolescent girl. *J Pediatr Gastroenterol Nutr* 1986; 5: 159 – 162
- ² Ozuner G, Davidson P, Church J. Intussusception of the vermiform appendix; preoperative colonoscopic diagnosis of two cases and review of the literature. *Int J Colorectal Dis* 2000; 15: 185 – 187

Corresponding Author

A. de Hoyos, M.D.

Camino a Santa Teresa No. 1055-119
Col. Héroes de Padierna

Delegación Magdalena Contreras
10700 México City

Mexico

E-mail: andehoyos@yahoo.com