Endoscopic Ultrasound-Guided Drainage of a Biloma: A Novel Approach

UCTN

A 42-year-old man with symptoms of cholecystitis underwent open cholecystectomy. The gallbladder was found to be distended with pus and the dilated cystic duct contained a stone. The common bile duct was not explored. He was referred to our hospital 30 days later with a 1-week history of fever and progressive jaundice, associated with pain and tenderness over the right upper quadrant of his abdomen. Computed tomography of his abdomen confirmed that there was a fluid collection in the gallbladder fossa (Figure **1**), with a mildly dilated common bile duct.

Figure **1** Computed tomographic image showing a large collection of fluid in the gallbladder fossa.

An endoscopic retrograde cholangiogram performed the following day revealed a bile leak from the cystic duct stump and a stone in the proximal common bile duct. Sphincterotomy was performed and the stone was removed using a Dormia basket. A 10-cm-long 10-Fr plastic biliary endoprosthesis (Wilson-Cook Medical Inc., Winston-Salem, North Carolina, USA) was inserted. Using a linear echo endoscope (Olympus UCP 160; Olympus Co., Tokyo, Japan), a 6 cm × 5 cm fluid collection was visualized in the gallbladder fossa. A 19-guage Wilson-Cook needle was introduced and 180 ml of bile was aspirated, emptying the collection (Figure **2**). The patient made a complete symptomatic recovery, with resolution of his fever and jaundice and improvement in his biochemical markers.

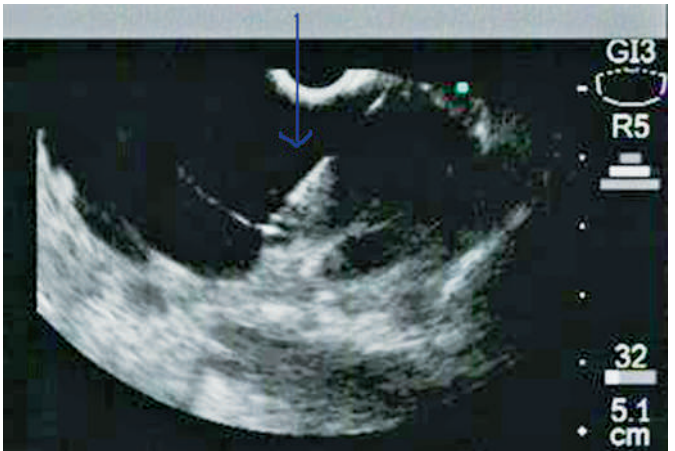

Figure **2** Endoscopic ultrasound image showing the 19-guage needle within the biloma.

A repeat endoscopic ultrasound was performed 2 weeks later which confirmed complete resolution of the fluid collection. He was electively readmitted 6 weeks later for stent removal, and cholangiography at that time revealed no evidence of a further bile leak. Two months later he had a transabdominal ultrasound examination, which confirmed the resolution of his biloma, and he remains well.

Endoscopic ultrasound-guided fine-needle aspiration of the infected biloma, together with endoscopic biliary stent placement, resulted in complete resolution of this patient's biloma, with no further reaccumulation of bile in the gallbladder fossa. This was a safe, simple, and effective procedure that was used to treat a patient with a potentially complex problem.

Competing interests: None

Corresponding Author

R. Ponnudurai, M.D.

Hepatology Unit
Selayang Hospital
Lebuhraya Selayang Kepong
Batu Caves
Selangor 68100
Malaysia
Fax: +60-361207564
E-mail: ryanmd66@hotmail.com

This document was downloaded for personal use only. Unauthorized distribution is strictly prohibited.