

Massive subcutaneous emphysema after attempted endoscopic retrograde cholangiopancreatography in a patient with a history of bariatric gastric bypass surgery

UCTN

Subcutaneous emphysema has been reported as a rare complication of diagnostic endoscopic procedures. We report a case of subcutaneous emphysema after failed endoscopic retrograde cholangiopancreatography in a 56-year-old woman who had previously undergone bariatric Roux-en-Y gastrojejunostomy and who was suspected to have sphincter of Oddi dysfunction.

A pediatric colonoscope was advanced through the gastric pouch and jejunal limb into the Roux limb, but we were unable to reach the papilla. No significant trauma occurred on scope withdrawal, and no other pathological abnormality was found. Immediately after the procedure, the patient's neck and face were noted to be edematous. A chest radiograph showed subcutaneous emphysema (Figure 1); and abdominal computed tomography revealed retroperitoneal air (Figure 2). Neither computed tomography nor an upper gastrointestinal series showed any contrast extravasation from the gastrointestinal tract. The patient was hemodynamically stable, but the emphysema persisted and exploratory laparotomy was performed. No perforation was found. The patient was eventually discharged in good condition, without any residual emphysema.

Subcutaneous emphysema following diagnostic endoscopy, where there is no increased risk of perforation, has been described previously [1,2]. The underlying mechanism is spread of air through deep fascial planes to subcutaneous tissue, and there are two main origins of air leakage. The first is from the alveolar space, due to increased airway pressure after air insufflation [3,4]; the second is from the gastrointestinal tract following mucosal disruption [3], which may occur during endoscopy. In the absence of obvious perforation, patients who develop subcutaneous emphysema typically have a potential site of weakness of the gastrointesti-

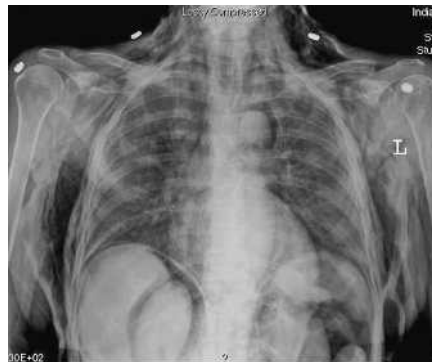

Figure 1 A chest radiograph after the endoscopy showed pneumoperitoneum and pneumomediastinum, with extensive subcutaneous emphysema surrounding the chest wall bilaterally, extending into the neck region.

nal tract adjacent to the retroperitoneum, such as a duodenal diverticulum in the afferent limb in a patient with Billroth II anatomy [1], or have undergone an antral biopsy during routine upper endoscopy [2]. In our patient, the gastro-enteric or entero-enteric anastomoses formed at bariatric surgery were potential sites of leakage. The fact that no perforation was found during laparotomy and the spontaneous resolution of the emphysema in this patient support the predominant view in the literature, namely that the passage of air through the intestinal wall does not necessarily imply perforation. Conservative management is appropriate, once noninvasive procedures have excluded an obvious perforation.

Endoscopy_UCTN_Code_CPL_1AK_2AJ

P. Mosler, E. L. Fogel
Indiana University Medical Center,
Indianapolis, Indiana, USA.

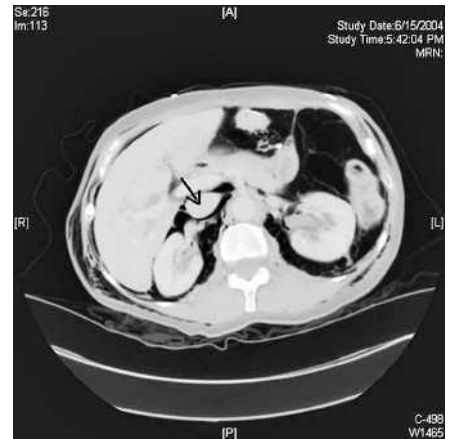


Figure 2 Abdominal computed tomography revealed that the patient had pneumoretroperitoneum, with air surrounding the inferior vena cava (arrow) and the right kidney.

References

- 1 Girardi A, Piazza I, Giunta G, Pappagallo G. Retroperitoneal, mediastinal and subcutaneous emphysema as a complication of routine upper gastrointestinal endoscopy. *Endoscopy* 1990; 22: 83–84
- 2 Fireman Z, Bar-Ziv I, Lurie B. Retroperitoneal, mediastinal, and subcutaneous emphysema as a complication of routine upper gastrointestinal endoscopy. *Endoscopy* 1994; 26: 329–330
- 3 Maklin C. Transport of air along sheaths of pulmonic blood vessels from alveoli to mediastinum. *Arch Int Med* 1939; 64: 72
- 4 Fayman M, Dunn S, Wellsted M. Two unusual complications related to fibre-optic endoscopy. *S Afr Med J* 1984; 65: 354

Corresponding author

P. Mosler, M. D.
Gastroenterology Associates Fulda
Bahnhofstr. 16
36037 Fulda
Germany
Fax: +49-661-3809229
Email: patrick.mosler@web.de

DOI: 10.1055/s-2006-925181