Acute gastric ulcer associated with gamma knife treatment (conformal stereotactic radiotherapy) of recurrent hepatocellular carcinoma

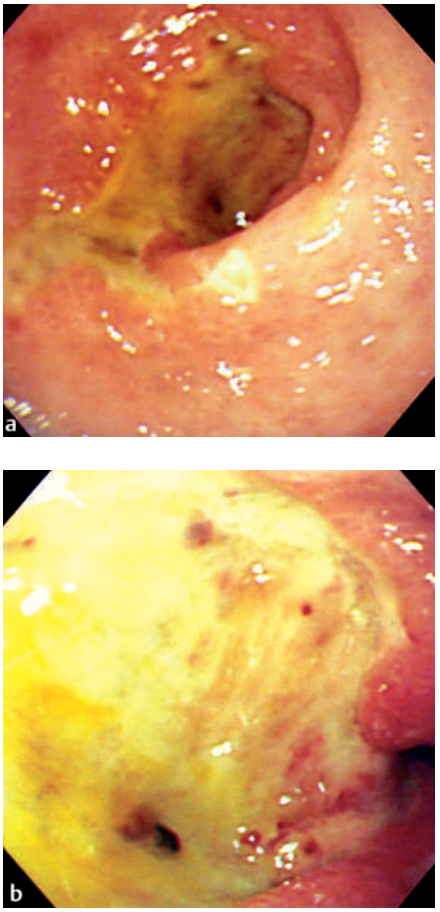

Figure **1** A 73-year-old man received one course of gamma knife radiotherapy (conformal stereotactic radiotherapy) for recurrent hepatocellular carcinoma, with a total dose of 45 Gy given within 1 month. Three days after finishing radiotherapy, he developed tarry stools. At esophagogastroduodenoscopy, he was found to have a large gastric ulcer on the lesser curvature and the anterior wall of the antrum, which had an irregular shape and margins (**a**) and several exposed vessels (**b**).

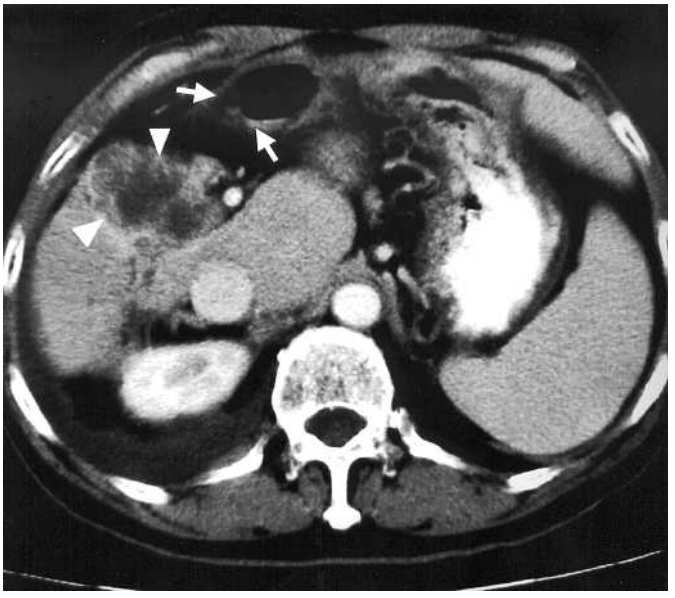

Figure **2** Abdominal computed tomography showed that there was a close anatomic relationship between the gastric antrum (arrows) and the hepatocellular carcinoma in the residual left hepatic lobe (arrowheads).

C. Y. Chang[1], C. H. Tu[1], T. S. Chiang[1], H. P. Wang[2]

[1] Department of Internal Medicine, E-DA Hospital, Kaohsiung, Taiwan

[2] Department of Emergency Medicine, National Taiwan University Hospital and National Taiwan University College of Medicine, Taipei, Taiwan

Endoscopy_UCTN_Code_CCL_1AB_2AD_3AC

Corresponding Author

H. P. Wang M. D.

Department of Emergency Medicine
National Taiwan University Hospital
No. 7 Chung-Shan South Road
Taipei
Taiwan
Fax: +886-2-23947899
E-mail: whp@ha.mc.ntu.edu.tw

DOI: 10.1055/s-2006-925190

This document was downloaded for personal use only. Unauthorized distribution is strictly prohibited.