

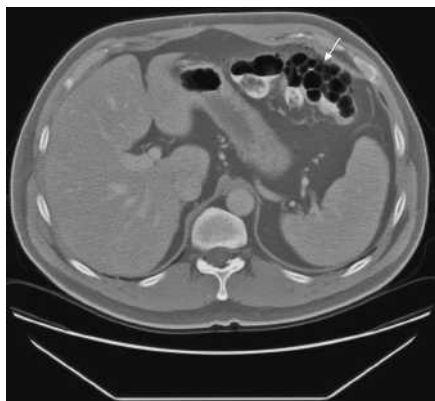Figure 1 A 47-year-old man presented with a 2-week history of mid-abdominal pain. He denied having any fever, chills, nausea, vomiting, or diarrhea. Computed tomography of the abdomen revealed numerous air-filled cysts involving the splenic flexure of the colon (arrow), a finding consistent with pneumatosis coli. A colonoscopy examination was then performed, which revealed sigmoid diverticulosis.

**T. E. Yusuf¹, S. C. Abraham²,
S. W. Trenkner³**

¹ Division of Gastroenterology and Hepatology, Mayo Clinic, Rochester, Minnesota, USA

² Division of Anatomic Pathology, Mayo Clinic, Rochester, Minnesota, USA

³ Department of Radiology, Mayo Clinic, Rochester, Minnesota, USA

Corresponding Author

T. E. Yusuf M.D.

Advanced Endoscopy Unit
Division of Gastroenterology
and Hepatology
Blake 4 Massachusetts General Hospital
55 Fruit Street
Boston
Massachusetts 02114
USA

Fax: +1-617-724-5997

E-mail: tyusuf@partners.org

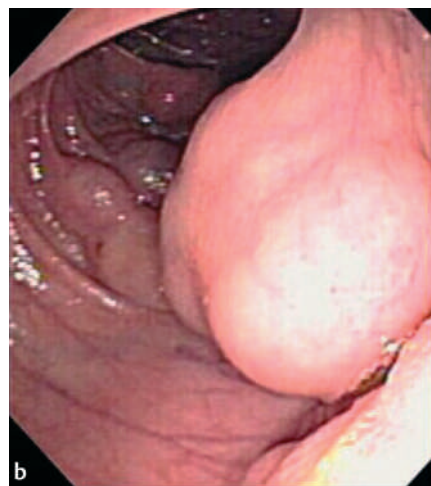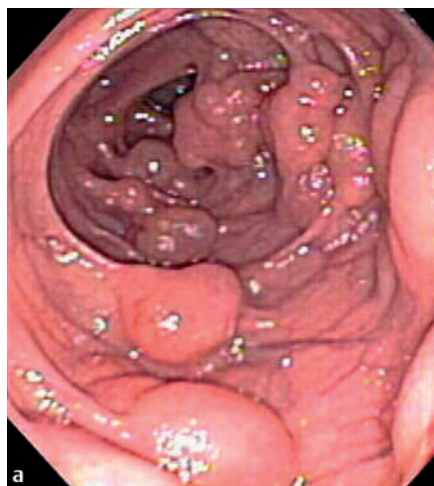


Figure 2 Multiple large, intramural, cyst-like structures were seen at the level of the splenic flexure at colonoscopy.

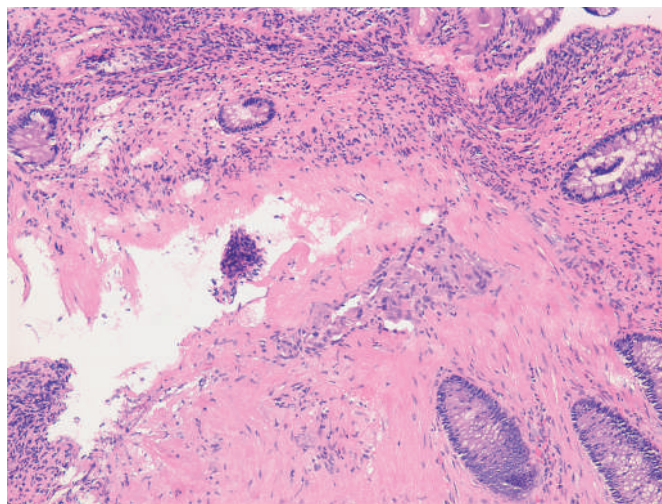


Figure 3 Histopathologic examination of biopsy specimens revealed cystic air-filled spaces within the submucosa which were partially lined by clusters of foreign-body macrophages (hematoxylin & eosin stain, magnification $\times 10$). A few weeks later the patient developed a perforated diverticulitis, which was managed medically; sigmoidectomy is planned.