

A 73-year-old man with end-stage renal disease, who was hemodialysis-dependent, was referred for investigation because he complained of feeling too quickly satiated and because he had lost weight. An esophagoscopy revealed a blind pouch in the distal esophagus, which was filled with retained food and secretions. This was occluding the distal esophagus. There seemed to be areas of necrotic mucosa in the pouch. After clearing of the retained material the gastroesophageal junction was identified and the stomach and duodenum were entered. Because of the patient's malnourished state, a feeding tube was passed into the stomach under direct vision (Figure 1).

After we had performed this procedure, an earlier upper gastrointestinal study was found which demonstrated the epiphrenic diverticulum noted at endoscopy, as well as a dilated esophagus with a smooth, tapered narrowing at the gastroesophageal junction, characteristic of achalasia (Figure 2). Because of the patient's many other medical problems no definitive therapy was undertaken and he continued on enteral feeding.

An epiphrenic diverticulum is an uncommon endoscopic finding, occurring only about a fifth as commonly as a Zenker's diverticulum [1]. Although usually asymptomatic, epiphrenic diverticula have been associated with dysphagia, weight loss, aspiration, and bleeding. In a similar way to colonic diverticula, epiphrenic diverticula arise due to herniation of the mucosa and submucosa through the muscular layer and occur in the setting of a motility disorder. Most commonly this motility problem is achalasia, which causes functional distal obstruction. For the symptomatic patient, treatment includes diverticulectomy and myotomy, which can be performed laparoscopically [2].

Endoscopy_UCTN_Code_CCL_1AB_2AC_3AF

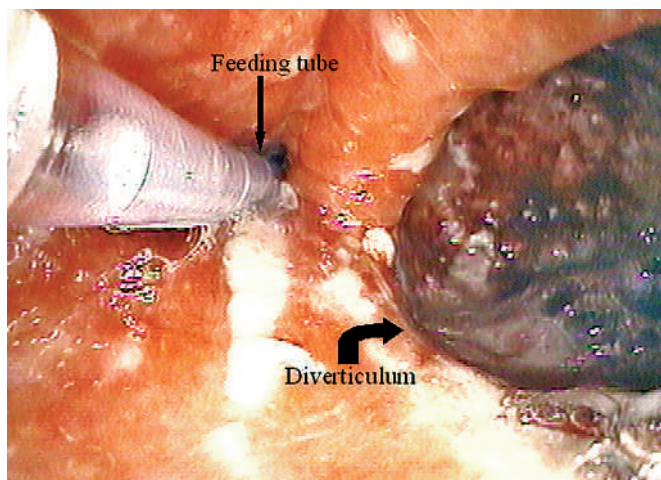


Figure 1 Endoscopic view of an epiphrenic diverticulum. The feeding tube can be seen entering the stomach.

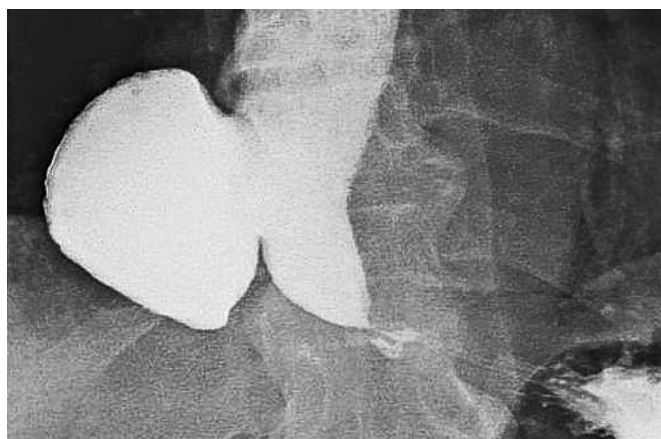

Figure 2 Barium radiograph showing an epiphrenic diverticulum with a "bird's beak" configuration of the distal esophagus.

G. Weitzman, C. Maltz

Division of Gastroenterology and Hepatology, Weill Cornell Medical School, New York, NY, USA.

References

- Achkar E. Esophageal diverticula. In: Castell DO, Richter JE (eds). The esophagus. 4th edn. Philadelphia: Lippincott, Williams and Wilkins 2004: 325–339
- Matthews B, Nelms C, Lohr C et al. Minimally invasive management of epiphrenic esophageal diverticula. Am Surg 2003; 69: 465–470

Corresponding author

C. Maltz, M.D.

Division of Gastroenterology and Hepatology
Weill Cornell Medical School
520 East 70th Street
New York
New York 10021
USA

Fax: +1-212-746-4734

E-mail: charles_maltz@post.harvard.edu