

A 63-year-old woman who had been diagnosed with Crohn's disease at the age of 58 was referred to our institution because she was experiencing frequent exacerbations while on treatment with budesonide and 5-aminosalicylate. Her treatment was changed to azathioprine but she did not show any clinical improvement and required hospital admission because of abdominal pain and diarrhea. An initial colonoscopy was terminated prematurely when we reached a tight stenosis in the left colonic flexure. A therapeutic colonoscopy with through-the-scope (TTS) balloon dilatation was performed and revealed two additional stenoses, in the transverse colon and in the ascending colon. The ileum was not involved.

To our surprise, we found an azathioprine pill in its original blister pack between the two proximal stenoses (Figure 1). After receiving instruction on how to take medications, we hope that the patient will now experience improved azathioprine efficacy.

Endoscopy\_UCTN\_Code\_CCL\_1AD\_2AH

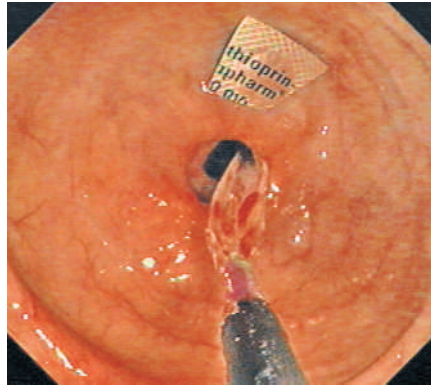


Figure 1 The azathioprine pill in its blister pack that we found in the ascending colon.

**M. Storr, B. Göke, A. Wagner**

Department of Medicine II,  
Klinikum Grosshadern,  
Ludwig-Maximilians-University of  
Munich, Munich, Germany.

### Corresponding Author

**M. Storr, M. D.**

Department of Medicine II  
Klinikum Grosshadern  
Ludwig-Maximilians-University of  
Munich  
Marchioninistraße 15  
81377 Munich  
Germany  
Fax: +49-89-7095-5281  
E-mail: martin.storr@med.  
uni-muenchen.de