

A 65-year-old man was admitted to hospital with obstructive jaundice. Three years previously he had been diagnosed with pulmonary tuberculosis. During his antituberculous treatment he was found to have a 10-cm cystic mass in the anterior mediastinum that was increasing in size. Computed tomography-guided biopsy showed this to be an epithelial neoplasm with neuroendocrine differentiation. This was surgically removed and pathological examination revealed a moderately differentiated neuroendocrine carcinoma of the thymus. There was focal involvement of the resection margin and lymphovascular spread. He was given postoperative adjuvant radiotherapy and remained well for 2 years.

After admission, ultrasound examination showed a 4-cm mass at the pancreatic head with common bile duct dilatation. Endoscopic retrograde cholangiopancreatography showed a distal common bile duct stricture. Subsequent computed tomography showed a heterogeneously enhanced, 4-cm mass at the head of pancreas, together with multiple necrotic hepatoduodenal nodes (Figure 1). The features were highly suggestive of pancreatic carcinoma. Endoscopic ultrasound-guided fine-needle aspiration was performed and bloody aspirate was obtained (Figure 2).

Cytology examination showed atypical cells with enlarged nuclei with a stippled chromatin pattern, and a small to moderate amount of cytoplasm (Figure 3a). Immunostaining demonstrated that these cells were positive for cytokeratins, including AE1/3 and CK7, and the neuroendocrine markers, chromogranin and synaptophysin (Figure 3b). The cytologic morphology was identical to that of the previously resected thymic cancer. A diagnosis of metastatic thymic neuroendocrine carcinoma was made, and he was referred for chemotherapy.

Thymic neuroendocrine carcinomas are rare and encompass a wide spectrum of

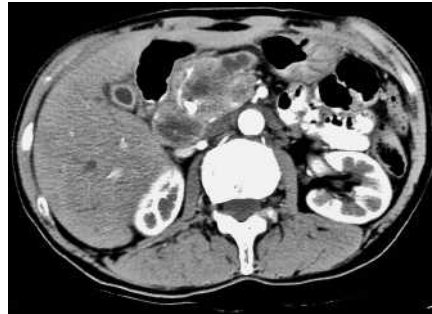

Figure 1 Computed tomographic scan showing an irregularly enhancing mass at the head of the pancreas.

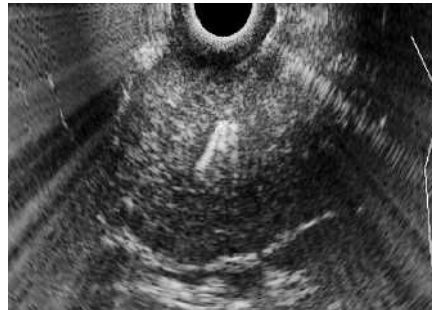


Figure 2 Endoscopic ultrasound-guided fine-needle aspiration of the tumor mass.

lesions, ranging from well- to moderately differentiated tumors (carcinoid or atypical carcinoid) to poorly differentiated carcinoma (small-cell carcinoma), different types sometimes being found within the same tumor [1]. Complete surgical excision is the most important determining factor for predicting long-term survival [2,3]. Metastatic spread of thymic cancer to bone, lung, pleura, spleen, brain, and mediastinal lymph nodes has been reported [4]. However, as far as we know, there has only been one case of pancreatic metastasis reported in the literature previously [5]. In the current case, endoscopic ultrasound-guided fine-needle aspiration was shown to be a valuable tool in reaching a diagnosis of this metastatic disease and major surgery was avoided.

Endoscopy_UCTN_Code_CCL_1AF_2AZ_3AB

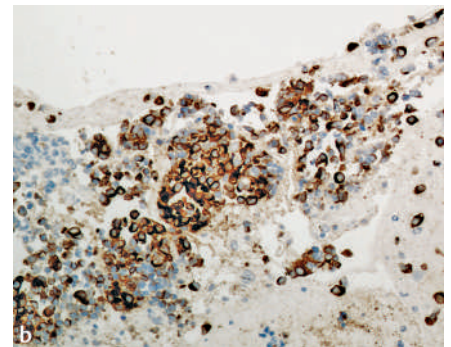
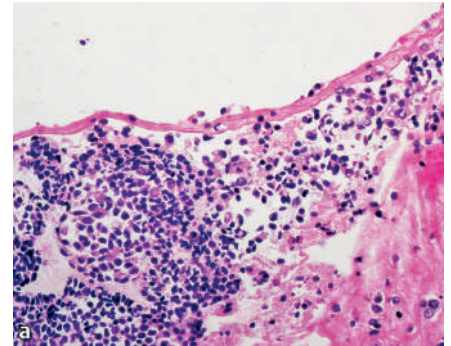


Figure 3 Histological views of the resected tumor. **a** Cell-block material showing clusters of tumor cells with small hyperchromatic nuclei and a moderate amount of cytoplasm (hematoxylin and eosin stain, magnification $\times 200$). **b** The same clusters of tumor cells after immunohistochemical staining, expressing chromogranin with strong cytoplasmic positivity (chromogranin stain, magnification $\times 200$).

Y. T. Lee¹, G. M. Tse², P. B. S. Lai³,
J. J. Y. Sung¹

¹ Department of Medicine and Therapeutics, Prince of Wales Hospital, The Chinese University of Hong Kong, Hong Kong

² Department of Anatomical and Cellular Pathology, Prince of Wales Hospital, The Chinese University of Hong Kong, Hong Kong

³ Department of Surgery, Prince of Wales Hospital, The Chinese University of Hong Kong, Hong Kong.

DOI: 10.1055/s-2006-944714

References

- ¹ Suster S, Moran CA. Thymoma classification: current status and future trends. *Am J Clin Pathol* 2006; 125: 542–554
- ² Suster S, Moran CA. The mediastinum. In: Weidner N, Cote R, Suster S et al (eds). *Modern surgical pathology*. Philadelphia, Pennsylvania: Saunders 2003: 439–504
- ³ Kim DJ, Yang WI, Choi SS et al. Prognostic and clinical relevance of the World Health Organization schema for the classification of thymic epithelial tumors: a clinicopathologic study of 108 patients and literature review. *Chest* 2005; 127: 755–761
- ⁴ Fukai I, Masaoka A, Fujii Y et al. Thymic neuroendocrine tumor (thymic carcinoid): a clinicopathologic study in 15 patients. *Ann Thorac Surg* 1999; 67: 208–211
- ⁵ Axelson J, Kobari M, Furukawa T et al. Thymic carcinoid in the pancreas: metastatic disease or new primary tumours. *Eur J Surg* 1999; 165: 270–273

Corresponding Author

Y. T. Lee, M.D.

Prince of Wales Hospital
The Chinese University of Hong Kong
Shatin, N.T.
Hong Kong SAR
China
Fax: +852-2637-5396
E-mail: leeytong@cuhk.edu.hk