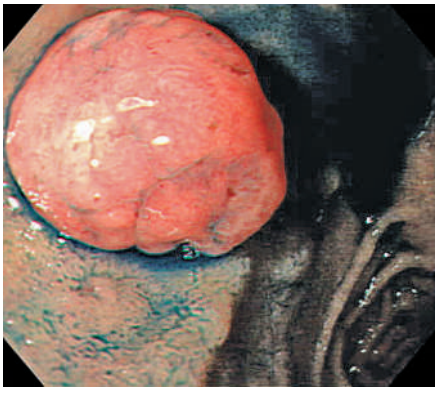

Figure **1** The duodenal polypoid lesion at chromoendoscopy.

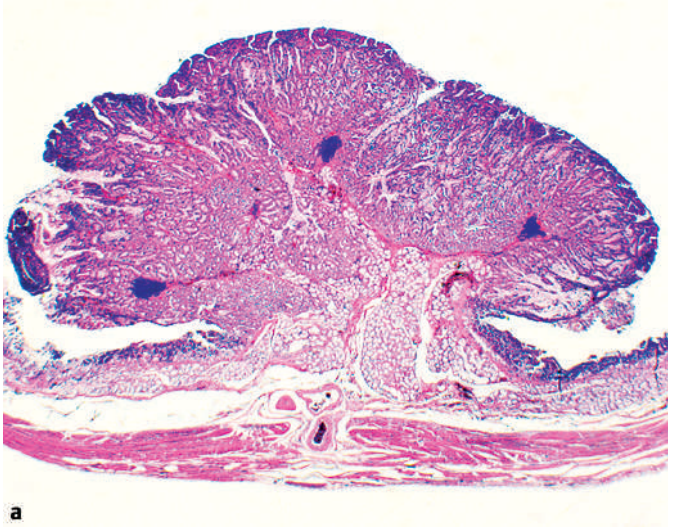

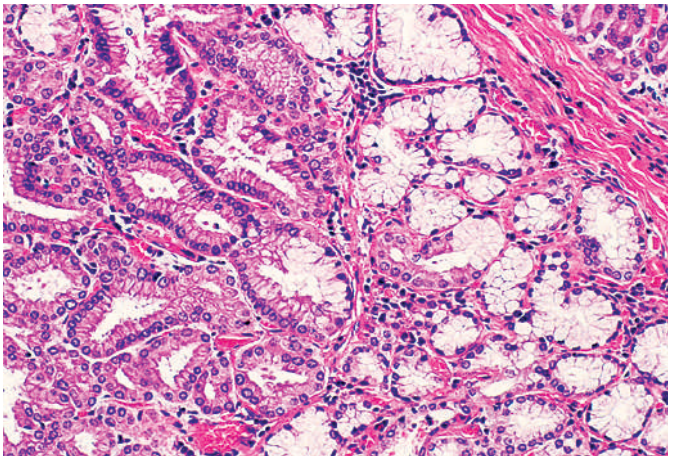

Figure **2** **a**, **b** The histological appearance of the polypoid lesion, showing the transition from the Brunner's gland hyperplastic area to the adenomatous area. **a** Hematoxylin–eosin, original magnification × 30. **b** Hematoxylin–eosin, original magnification × 50.

Brunner's gland adenoma is an extremely rare neoplasm, which may be confused with Brunner's gland hyperplasia or hamartoma. The present report describes a case of "true" Brunner's gland adenoma resected by surgery.

An 82-year-old man with a duodenal polyp was admitted to hospital for surgical treatment of newly diagnosed gastric cancer. Gastroduodenoscopy revealed a 12-mm subpedunculated polypoid lesion, covered with smooth, reddish mucosa, in the duodenal bulb (Figure **1**). Distal gastrectomy was carried out for the gastric cancer and for the duodenal polypoid lesion.

Histologically, the duodenal polypoid lesion was found to consist of Brunner-like glands with moderate nuclear atypia. Nonneoplastic Brunner's gland hyperplasia was seen at the basal side of the polypoid lesion (Figure **2**). Figure **2 b** shows the transition from the hyperplastic area to the adenomatous area. Immunohistochemically, the adenomatous Brunner-like glands were positive for MUC6, showing that they originated from Brunner's glands. The surface of the polypoid lesion was covered with gastric foveolar-like glands.

Brunner's gland adenoma is extremely rare, representing only 10.6% of benign duodenal tumors [1], which are themselves rare at 0.008% of all surgical and autopsy specimens. Matsumoto et al. reported a case of a large Brunner's gland adenoma removed by endoscopic polypectomy [2]. Fujimaki et al. reported a case of duodenal polypoid lesion consisting mainly of hyperplastic Brunner's glands, but with a focus of atypical glands consisting of cells with nuclear atypia [3]. There have been reports of neoplasia occurring in Brunner's gland hyperplasia [4]. The present case shows a transition from a hyperplastic area in the Brunner's glands to an adenomatous area, showing that a "true" Brunner's gland adenoma can exist and suggesting its etiology.

Endoscopy_UCTN_Code_CCL_1AB_2AZ_3AB

DOI: 10.1055/s-2006-945023

This document was downloaded for personal use only. Unauthorized distribution is strictly prohibited.

K. Suda[1], S. Hamada[1], M. Takahashi[1], Y. Kumashiro[2], T. Yao[2], K. Sugimachi[3], D. Korenaga[3], K. Takenaka[3]

[1] Dept. of Internal Medicine, Fukuoka City Hospital, Fukuoka, Japan
[2] Dept. of Anatomic Pathology, Kyushu University, Fukuoka, Japan
[3] Dept. of General Surgery, Fukuoka City Hospital, Fukuoka, Japan.

References

[1] Nakanishi T, Takeuchi T, Hara K, Sugimoto A. A great Brunner's gland adenoma of the duodenal bulb. Dig Dis Sci 1984; 29: 81 – 85
[2] Matsumoto T, Iida M, Matsui T et al. A large Brunner's gland adenoma removed by endoscopic polypectomy. Endoscopy 1990; 22: 192 – 193
[3] Fujimaki E, Nakamura S, Sugai T, Takeda Y. Brunner's gland adenoma with a focus of p53-positive atypical glands. J Gastroenterol 2000; 35: 155 – 158
[4] Doi K, Tada S, Fujimoto T et al. Successful endoscopic removal of a duodenal adenoma occurring in Brunner's gland hyperplasia. Dig Endosc 2004; 16: 148 – 151

Corresponding author

K. Suda, M.D.

Dept. of Internal Medicine
Fukuoka City Hospital
Yoshizuka-honmachi 13-1
Fukuoka 812-0046
Japan
Fax: +81-92-632-0900
Email: md199055@yahoo.co.jp

This document was downloaded for personal use only. Unauthorized distribution is strictly prohibited.