

An 87-year-old woman presented at the emergency room with breathlessness and acute chest pain following an outpatient colonoscopy that was carried out 2 hours earlier. She suffered from chronic coronary disease and hypertension, and was taking medication for both conditions. The endoscopy was very painful. Abdominal discomfort was accompanied by a dull, heavy pain in the center and right side of the chest, radiating to the right shoulder. Retrosternal ailments were worsening (hypoxia, hypotension, tachycardia). Physical examination revealed moderately, dull respiratory murmur, and tympanic percussion note on the right side. Lower abdomen discomfort was also worsening. Radiographs revealed perforation, intestinal pneumatosis, and right-sided pneumothorax (Figure 1). Concomitant myocardial infarction and other pathologies were excluded.

A chest drain tube with underwater seal was inserted to evacuate pneumothorax. Surgery was performed immediately and revealed severe pneumatosis of large bowel, retroperitoneum, and proximal parts of the gastrointestinal tract (Figure 2). Neither fluid nor direct communication of the bowel lumen with the peritoneal cavity was found. The diaphragm was intact. A 2-cm hole was found at antimesenteric sigmoid epiploic appendix, without perforation of serosa (Figure 3). The perforation was closed with two layers of primary interrupted stitches (Figure 4). The hospitalization and 6-month follow-up were uneventful.

Pneumothorax and intestinal pneumatosis may accompany colon perforation and are relatively rare [1–5]. Usually, chest pain or clinical deterioration of an older patient is considered acute myocardial ischemia. Although myocardial infarction develops in only 0.12% of endoscopies in the general population [3], the number rises to 16% in patients with severe coronary heart disease [4]. In our case, acute chest symptoms were the manifestation of iatrogenic perforation of the sigmoid.

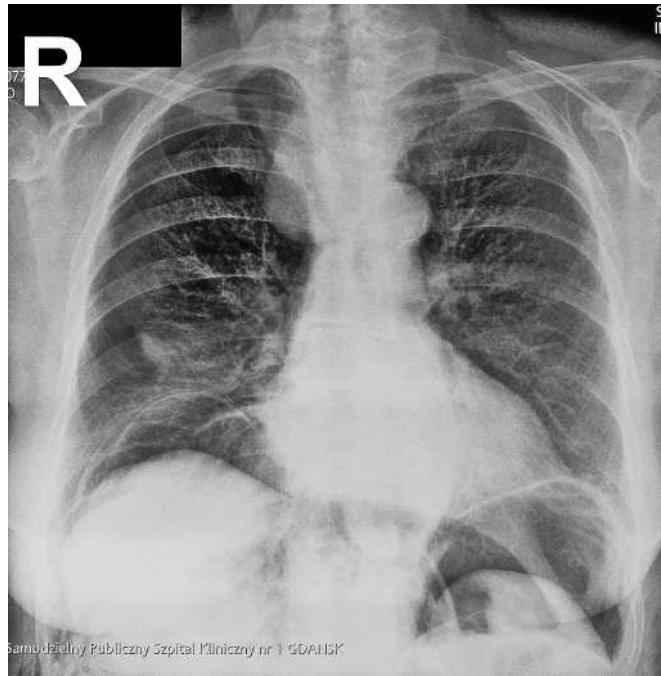

Figure 1 Plain chest radiogram. Right pneumothorax and free air below diaphragm on both sides.

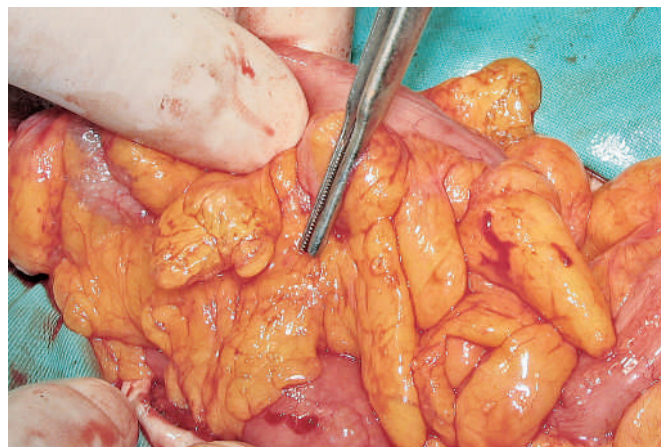


Figure 2 Intraoperative retroperitoneal and mesenteric pneumatosis without visible peritoneal tear.

The reasons for low abdominal symptoms were good bowel preparation and completely retroperitoneal perforation.

In conclusion, apart from pain of cardiac origin, retrosternal pain in patients undergoing colonoscopy can be due to iatrogenic pneumothorax. It should be considered in clinically deteriorating patients suffering from periprocedural acute chest pain.

Endoscopy_UCTN_Code_CPL_1AJ_2AB

S. Hac, J. Kobiela, W. Puzdrowski, Z. Sledzinski

Department of General, Endocrine and Transplant Surgery, Medical University of Gdansk, Poland.

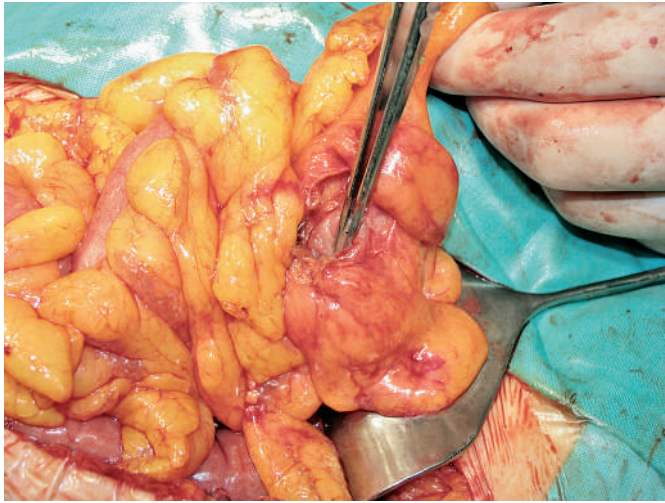

Figure 3 Sigmoid iatrogenic perforation within epiploic appendix visible after opening the visceral peritoneum.

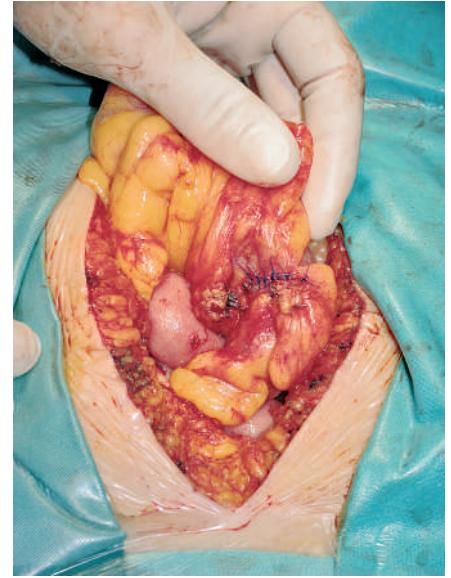


Figure 4 Final view of two-layer closure of sigmoid iatrogenic perforation.

References

- ¹ Kavic SM, Basson MD. Complications of endoscopy. *Am J Surg* 2001; 181: 319–332
- ² Ota H, Fujita S, Nakamura T et al. Pneumoperitoneum, pneumomediastinum, pneumopericardium and subcutaneous emphysema complicating sigmoidoscopy: report of a case. *Surg Today* 2003; 33: 305–308
- ³ Nelson DB, McQuaid KR, Bond JH et al. Procedure success and complications of large-scale screening colonoscopy. *Gastrointest Endosc* 2002; 55: 307–314
- ⁴ Lee JG, Krucoff MW, Brazer SR. Periprocedural myocardial ischemia in patients with severe symptomatic coronary artery disease undergoing endoscopy: prevalence and risk factors. *Am J Med* 1995; 99: 270–275
- ⁵ Waye JD, Lewis BS, Yessayan S. Colonoscopy: a prospective report of complications. *J Clin Gastroenterol* 1992; 15: 347–351

Corresponding author

S. Hac, MD

Department of General, Endocrine
and Transplant Surgery
Medical University of Gdansk
7 Debinki Street
80-211 Gdansk
Poland
Fax: +48-58-349-2410
Email: sthac@amg.gda.pl