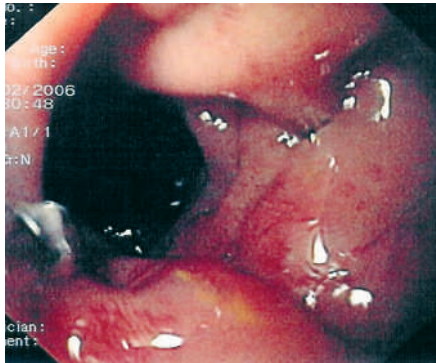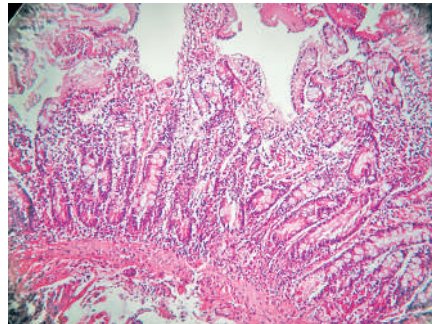


**Figure 1** Endoscopic view of the second part of the duodenum, which appears stenotic, with grossly thickened duodenal folds, an appearance similar to that of lymphoma. Very little distension was observed even at maximal air insufflation.

Eosinophilic gastroenteritis is a rare but important cause of abdominal pain of unknown etiology [1]. It can sometimes be recognized on the basis of macroscopic abnormalities, such as erythema, focal erosions, ulcerations, and thickening of mucosal folds [2]. Small-bowel obstruction can occur in eosinophilic gastroenteritis involving the muscularis layer [3], but gastric outlet obstruction is extremely rare [4].

In February 2006 we saw a 37-year-old man with a 6-month history of recurring episodes of vomiting, increased abdominal volume, and weight gain. He had marked peripheral eosinophilia (2500 cells/ $\mu$ L, 56% of the white blood cells). He underwent esophagogastroduodenoscopy, when gastric ectasia with pyloric stenosis was found; the duodenal bulb and the second part of the duodenum up to major papilla were also stenosed, with irregular, gross thickening of the duodenal folds, an appearance similar to that of lymphoma (Figure 1). Histological examination of duodenal and gastric specimens showed numerous eosinophils in the lamina propria (Figure 2). Computed tomography was performed, which showed marked gastric ectasia, thickening of the walls of the distal gastric antrum and the first part of the duodenum, and marked ascites (Figure 3).

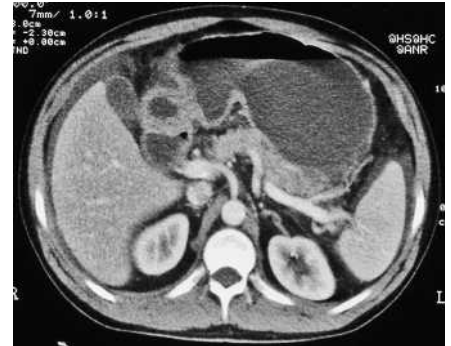

**Figure 2** Histological examination showed massive infiltration of eosinophils throughout the duodenal wall (hematoxylin and eosin stain, magnification  $\times 100$ ).

After exclusion of parasitic infestation by stool culture, and on the basis of the serological, radiological, and histological findings, we made a diagnosis of gastric outlet obstruction due to eosinophilic gastroenteritis with involvement of the serosal layer. The patient was treated with prednisone 1 mg/kg/day and pantoprazole 80 mg/day. Within 7 days of starting this treatment he showed dramatic clinical improvement, with rapid weight loss, disappearance of the ascites, and early restoration of oral feeding. The patient is now symptom-free (July 2006), and is still receiving treatment with pantoprazole 40 mg/day. The endoscopic, histological, and radiological examinations performed at this time showed that the previously affected areas in the stomach and duodenum were of normal appearance.

This is the first case report describing eosinophilic gastroenteritis with gastric outlet obstruction and ascites. This case shows that clinicians should be aware of this condition because it can mimic a wide variety of other intestinal diseases, and misdiagnosis could result in inappropriate therapy. Moreover, it confirms that endoscopic, histological, and radiological investigations are required to make the correct diagnosis in cases of gastric outlet obstruction.

Endoscopy\_UCTN\_Code\_CCL\_1AB\_2AD\_3AC



**Figure 3** Contrast-enhanced abdominal computed tomographic view (using intravenous and oral contrast) showing pronounced contrast enhancement with gastric ectasia, thickening of the antrum and the second part of the duodenum, and ascites.

**A. Tursi<sup>1</sup>, G. Rella<sup>2</sup>, C. D. Inchingolo<sup>2</sup>, M. Maiorano<sup>3</sup>**

<sup>1</sup> Digestive Endoscopy Unit, "Lorenzo Bonomo" Hospital, Andria (BA), Italy

<sup>2</sup> Division of Pathology, "Lorenzo Bonomo" Hospital, Andria (BA), Italy

<sup>3</sup> Department of Radiology, "Lorenzo Bonomo" Hospital, Andria (BA), Italy.

## References

- 1 Khan S. Eosinophilic gastroenteritis. *Best Pract Res Clin Gastroenterol* 2005; 19: 177–198
- 2 Katsumi N, Yamagichi Y, Yamato T et al. Multiple ulcerative lesions of the stomach: a rare cause of eosinophilic gastroenteritis. *Gastrointest Endosc* 2002; 56: 762–764
- 3 Charalabopoulos A, Charalabopoulos K, Avuzklidou M et al. Eosinophilic gastroenteritis: presentation of two patients with unusual affect of terminal ileum and caecum with manifestations of acute abdomen and literature review. *Int J Clin Pract* 2004; 58: 413–416
- 4 Chen MJ, Chu CH, Lin SC et al. Eosinophilic gastroenteritis: clinical experience with 15 pateints. *World J Gastroenterol* 2004; 10: 2813–2816

## Corresponding author

**A. Tursi, MD**

Via Torino 49 · 70031 Andria (BA) · Italy

Fax: +39-0883-290394

Email: antotursi@tiscali.it

DOI: 10.1055/s-2006-945125