A new endoscopic therapy for an intraluminal diverticulum of the duodenum

UCTN

Figure **1** Conventional radiograph showing intraluminal diverticulum of the duodenum projecting within the lumen of the second duodenum.

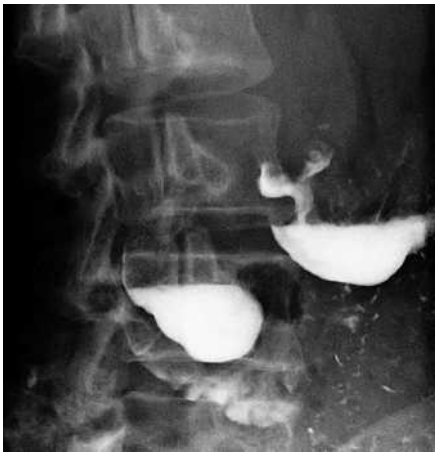

Figure **2** Barium retention in both the bulbus and intraluminal diverticulum of the duodenum.

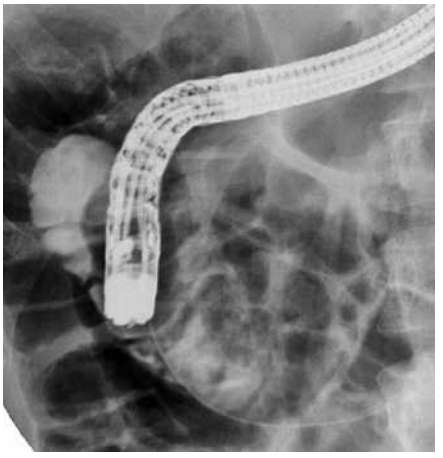

Figure **3** Hydrosoluble contrast injection in the diverticulum and in the duodenal lumen through the perforation of the diverticulum.

We report the case of a 33-year-old woman with dyspeptic symptoms and 5 kg weight loss in 5 months.

During upper gastrointestinal endoscopy at another institution, access to the second part of the duodenum had not been possible for reasons that were unclear. At our hospital, a barium follow through revealed a sac-like contrast-containing structure within the duodenal lumen, suggestive of an intraluminal diverticulum of the duodenum (IDD) (Figure **1** and **2**). Repeat endoscopy confirmed that the second portion of the duodenum could only be reached through a tiny passage at the level of the genu superius, laterally to the diverticular orifice.

After obtaining consent and with the aid of a therapeutic endoscope, we punctured the bottom of the diverticulum with a needle knife papillotome. A 0.035-inch guide wire was introduced in the hole, and hydrosoluble contrast material was injected above and below the puncture site to confirm the exact localization of the IDD (Figure **3**). Consequently the puncture site was enlarged using a 7-Fr cystogastrotome, allowing the introduction of an insulated-tip needle knife to incise the diverticular wall longitudinally,

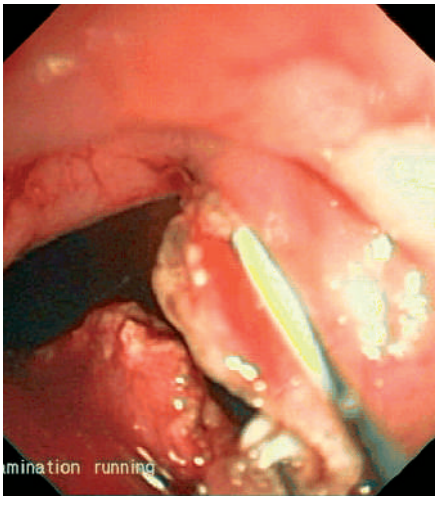

Figure **4** Endoscopic view from within the diverticulum, showing progression of the diverticulotomy using the insulated-tip knife; note the presence of the guide wire in the incision orifice.

Videos 1 – 3

Sequence **1** Inspection of the intraluminal diverticulum of the duodenum. Sequence **2** Perforation of the diverticular sac using a needle-knife papillotome. Sequence **3** Progressive incision of the diverticular septum with the insulated-tip knife.

Figure **5** Endoscopic view of the genu superius from the bulbus showing complete healing of the mucosa and patency of the duodenum.

up to the diverticular mouth at the genu superius (Figure **4** and video sequences). Endoscopic control with side-viewing scope identified both the papilla and the presumed location of the intramural part of the common bile duct laterally to the section. No immediate or delayed complication occurred. A control endoscopy was performed 1 month later showing complete healing and easy passage to the second duodenum (Figure **5**). Clinical evaluation, 8 months postprocedure revealed continued absence of the dyspeptic symptoms, and no additional weight loss.

DOI: 10.1055/s-2006-945175

This document was downloaded for personal use only. Unauthorized distribution is strictly prohibited.

IDD is a rare developmental anomaly found in adulthood [1–3]. The main symptoms are related to partial or intermittent obstruction. The most common complications include bleeding, acute or recurrent pancreatitis, cholangitis, and intussusception [3,4]. Several techniques of endoscopic management of IDD have been described [4,5]. The present procedure allows avoidance of trauma to the papilla, the common bile duct, or the opposite duodenal wall.

Endoscopy_UCTN_Code_TTT_1AO_2AN

A. Badaoui, H. Piessevaux
Department of Gastroenterology, Cliniques universitaires St-Luc, Brussels, Belgium.

References

1 De Castro ML, Hermo JA, Pineda JR et al. Acute bleeding and anemia associated with intraluminal duodenal diverticulum: case report and review. Gastrointest Endosc 2003; 57: 976–979
2 Ravi J, Joson PM, Ashok PS. Endoscopic incision of intraluminal duodenal diverticulum. Case report of a new technique. Dig Dis Sci 1993; 38: 762–766
3 Finnie IA, Ghosh P, Garvey C et al. Intraluminal duodenal diverticulum causing recurrent pancreatitis: treatment by endoscopic incision. Gut 1994; 35: 557–559
4 Lee SH, Park SH, Lee JH et al. Endoscopic diverticulotomy with an isolated-tip papillotome (Iso-Tome) in a patient with intraluminal duodenal diverticulum. Gastrointest Endosc 2005; 62: 817–819
5 Hiraoka T, Nakamura M, Ohno K et al. Endoscopic excision of intraluminal duodenal diverticulum. Dig Dis Sci 1985; 30: 274–281

Corresponding author

H. Piessevaux, MD
Department of Gastroenterology
Cliniques universitaires St-Luc
Université catholique de Louvain
Avenue Hippocrate 10
1200 Brussels
Belgium
Fax: +32-2-764-8927
Email: piessevaux@gaen.ucl.ac.be

This document was downloaded for personal use only. Unauthorized distribution is strictly prohibited.