Successful Extracorporeal Shock-Wave Lithotripsy for a Single Pancreatic Stone Located Outside of an Undilated Main Pancreatic Duct

Extracorporeal shock-wave lithotripsy (ESWL) is often used in the treatment of pancreatic stones, in association with endoscopic extraction when required (1,2). The aim is to lower the ductal pressure above a pancreatic stone (3,4). The procedure is usually carried out in order to avoid surgery in patients with dilation of the main pancreatic duct due to ductal obstruction by a large stone (1). We report here a case in which ESWL was used successfully in a patient who had previously undergone surgery. In this patient, a large stone located outside of the main pancreatic duct resulted in obstructive pancreatitis in the inferior part of the pancreatic head.

A 26-year-old man was admitted in March 1995 for epigastric pain. Familial pancreatitis had been diagnosed several years previously, and a pancreaticojejunostomy had been performed in 1987. He experienced recurrent episodes of pancreatic pain lasting one to three days during the following seven years. In June 1994, ultrasonography, computed tomography, and endosonography demonstrated an absence of dilation of the main pancreatic duct and a 15-mm calcified stone in the head of the pancreas, which was already visible on the plain abdominal radiograph. Endoscopic retrograde cholangiopancreatography (ERCP) showed a permeable anastomosis and a compression of the secondary pancreatic ducts in the lower part of the head by a 15-mm calcified stone (Figure **1**). A pancreatic sphincterotomy was performed. The same type of pain recurred in March 1995, and the patient was re-admitted. A single session of ESWL was performed, with a total of 3500 pulses and with a primary energy of 16.6 kV, using the Lithostar electromagnetic lithotriptor (Siemens). The treatment session lasted 45 minutes. During nine months of follow-up, the patient did not experience any further pain. Plain abdominal radiography and abdominal ultrasound confirmed that the stone had disappeared.

In this patient, there was a single obstructive pancreatic stone. This type of case is regarded as the best situation for ESWL, in association with endoscopic extraction (5). In published reports, ESWL has only been performed when the main pancreatic duct

This document was downloaded for personal use only. Unauthorized distribution is strictly prohibited.

was dilated (1). In the present patient, however, there was no dilation of the main duct, but an effective pancreaticojejunal anastomosis and pancreatic sphincterotomy. Only the lower pancreatic head ducts were dilated, with an appearance of localized obstructive pancreatitis. Failure of endoscopic treatment before ESWL often results from stenosis or kinking of the main pancreatic duct (3), or is due to the size of the stone (2). In the present patient, endoscopic treatment failed because the stone was located outside of the main pancreatic duct, which was not otherwise stenosed. This is the first case, as far as we are aware, in which the resolution of pain resulted from disappearance of a stone that was not obstructing the main pancreatic duct. This observation suggests that destruction and complete removal of an obstructive stone can relieve recurrent pancreatic pain, even though the stone is located outside of the main pancreatic duct, if there is a significant dilation of the secondary pancreatic ducts at the same time.

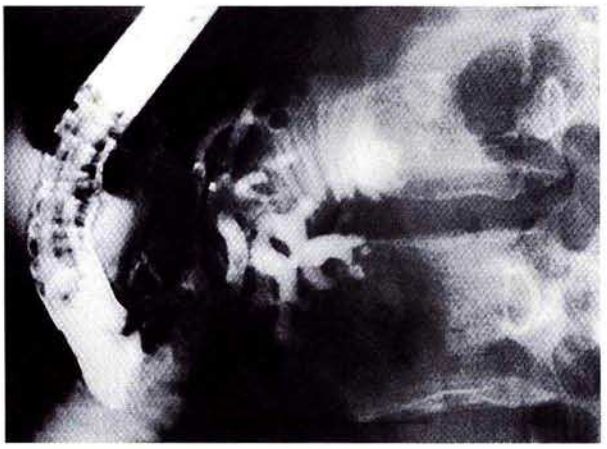

Figure 1: ERCP showing dilation of the secondary pancreatic ducts.

B. Védrenne[1], H. Hadjadj[2], P. Souillac[1], J. C. Coffin[3], G. Gatineau-Sailliant[1], M. Glikmanas[1]

[1] Dept. of Gastroenterology
[2] Dept. of Urology, Centre Hospitalier de Meaux, France
[3] Clinique de l'Europe, Port-Marly, France

References

1. Delhaye M, Vandermeeren A, Baize M, Cremer M. Extracorporeal shockwave lithotripsy of pancreatic calculi. Gastroenterology 1992; 102: 1406–11.
2. Sauerbruch T, Holl J, Sackmann M, Paumgartner G. Extracorporeal shockwave lithotripsy of pancreatic stones in patients with pancreatitis and pain: a prospective follow-up study. Gut 1992; 33: 969–72.
3. Sauerbruch T, Holl J., Sackmann M, Werner R, Wotzka R, Paumgartner G. Disintegration of a pancreatic duct stone with extracorporeal shock waves in a patient with chronic pancreatitis. Endoscopy 1987; 19: 207–8.
4. Neuhaus H. Fragmentation of pancreatic stones by extracorporeal shockwave lithotripsy. Endoscopy 1991; 23: 161–5.
5. Cremer M. L'endoscopie, traitement d'avenir de la pancréatite chronique? Gastroenterol Clin Biol 1993; 17: 787–91.

Corresponding Author
B. Védrenne, M.D.
Service d'Hépatogastroentérologie
Hôpital E. Muller
20, rue du Docteur Laënnec
BP 1370, 68070 Mulhouse
France
Fax: +33-0389647021

This document was downloaded for personal use only. Unauthorized distribution is strictly prohibited.