Two-Port Technique for Laparoscopic Cholecystectomy Using a Microendoscope

A two-port technique for laparoscopic cholecystectomy is described here, using a microendoscope. The method provides a good view of the porta hepatis (Figure **1 a**). The first port is a microendoscope in the umbilicus, introduced through the lumen of a Veress needle. The other is a 10-mm trocar. This may be the best approach in selected patients, instead of the standard four-trocar procedure. It probably reduces surgical trauma, and may be less painful than conventional laparoscopy.

The technique begins with a 2-mm transverse cutaneous incision, made in a supraumbilical position. A Veress needle is then introduced (Figure **1 b**). After pneumoperitoneum has been obtained, a microendoscope (Figure **2**) is passed through the Veress needle (Figure **1 b**). A 10-mm trocar in positioned under direct vision in the epigastric median line for instrumentation. Two or three sutures are separately passed across the abdominal wall to hold the gallbladder fundus and infundibulum (Figure **2**). This allows sound dissection and easy performance of intraoperative cholangiography. The gallbladder is removed through the epigastric cannula. A 0-degree laparoscope is then introduced through the epigastric cannula, for inspection.

Eight patients underwent laparoscopic cholecystectomy using this technique (mean operating time 90 minutes), with better cosmetic results than with the four-port technique. No intraoperative complications occurred. However, further studies are required to establish whether the minor parietal trauma associated with this procedure compensates for the inherent technical difficulties.

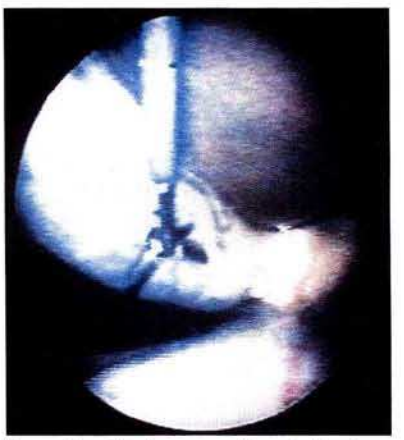

Figure 1 a: The image seen through the microendoscope.

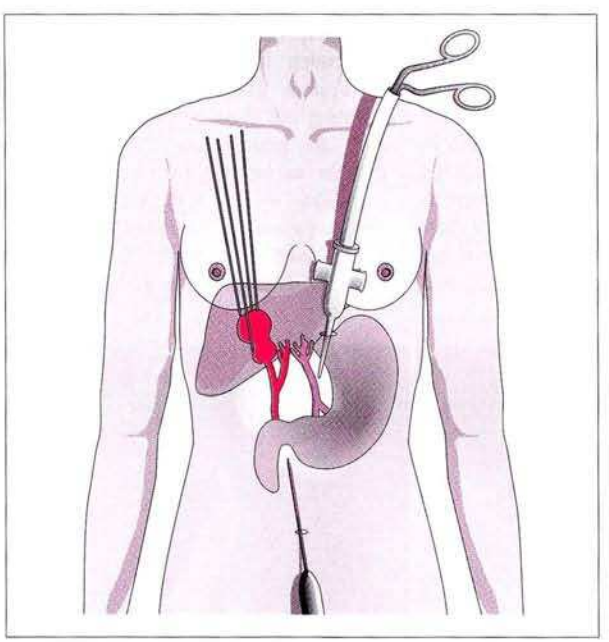

Figure 1 b: Insertion sites for the 10-mm trocar and microendoscope, and positioning of the sutures holding the infundibulum and fundus of the gallbladder.



Figure 2: The microendoscope system consists of a stainless-steel tube with a working length of 26.67 cm (1), a threaded male connector (2), a ferrule to the light source (3), a light cable (4), and a Veress needle (5).

S. Roll, J. L. M. C. Azevedo, W. Gorski, R. Abdalla, O. Azevedo
Affiliation, Santa Rita Hospital
São Paulo, Brazil

Corresponding Author
J. L. M. C. Azevedo, M.D.
Rua Coronel Lisboa, 805
04020-040 Vila Clementino
São Paulo, Brazil
Fax: 005511432-3957

This document was downloaded for personal use only. Unauthorized distribution is strictly prohibited.