

Images in Focus

A Signet-Ring Cell Carcinoma of the Stomach Endoscopically Recognized as a Tiny Discolored Spot

M. Sanaka¹, Y. Kuyama¹,
M. Yamanaka¹, Y. Tamura²

¹ Dept. of Internal Medicine,
Teikyo University, School of Medicine,
Tokyo, Japan

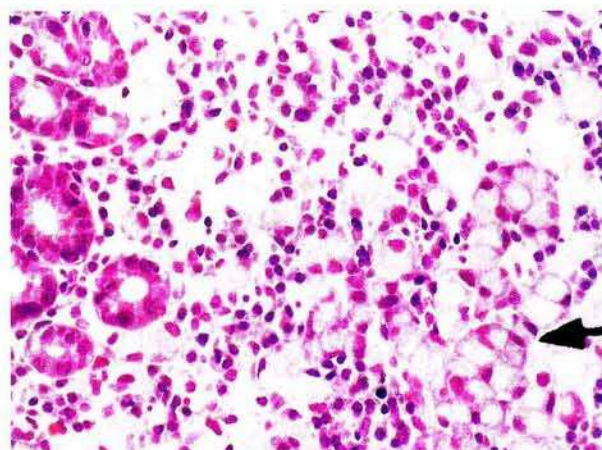
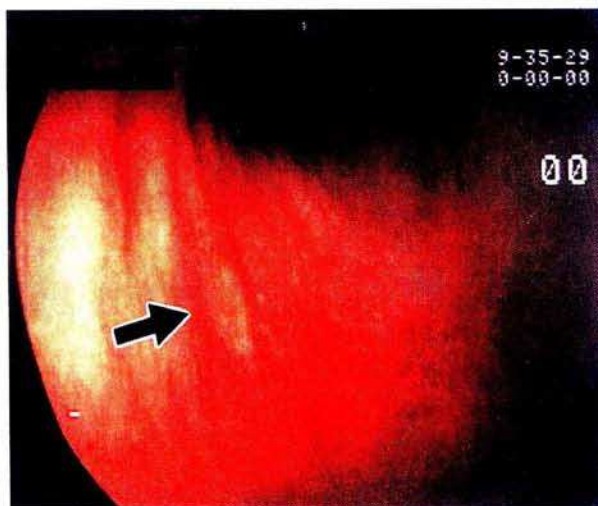
² First Dept. of Internal Medicine,
Tokyo Medical and Dental University,
School of Medicine, Tokyo, Japan

References

1. Oohara T, Aono G, Ukawa S, et al. Clinical diagnosis of minute gastric cancer less than 5 mm in diameter. *Cancer* 1984; 53: 162–5.
2. Hioki K, Nakane Y, Yamamoto M. Surgical strategy for early gastric cancer. *Br J Surg* 1990; 77: 1330–4.

Corresponding Author

M. Sanaka, M.D.
Dept. of Internal Medicine
Teikyo University School of Medicine
Kaga 2-11-1
Itabashi-ku
Tokyo 173
Japan
Fax: +81-3-3964-7094



A 4-mm diameter well demarcated slightly depressed discolored area (arrow) was seen in the anterior wall of the antrum in a 29-year-old woman (Figure 1) (1). It was biopsied twice. Since signet-ring cells were histologically identified (Figure 2, arrow), gastrectomy was carried out (2). Pathological examination showed that there was no residual cancer in the resected stomach. The signet-ring cell carcinoma was tiny, and had been completely removed by the two biopsies.