

Intraoperative Endoscopic Sphincterotomy During Laparoscopic Cholecystectomy

There are various strategies for treating common bile duct (CBD) stones identified during laparoscopic cholecystectomy. We describe here a technique of intraoperative endoscopic sphincterotomy (ES). The method is simple and easy to perform, even with the patient in the supine position.

An intraoperative cholangiogram was carried out in the usual manner during laparoscopic cholecystectomy, using a catheter from the cystic duct. An insulated guide wire (Olympus G35-2LD, diameter 0.035 inches, 5000 mm long, Olympus Optical Co., Tokyo, Japan) was inserted into the cholangiogram catheter and advanced through the duodenum. A front-viewing endoscope was advanced into the duodenum to pull the guide wire out through the stomach to the mouth, using a basket catheter. The front end of the guide wire was inserted in the opposite direction into a pull-type sphincterotome (Olympus KD7-G7Q, Olympus Optical Co., Tokyo, Japan) mounted in the working channel of a side-viewing endoscope. The guide wire was carefully held tense by an endoscopist and a laparoscopist in such a way that the side-viewing endoscope could be advanced into the duodenum smoothly. Cannulation of the sphincterotome into the papilla and endoscopic sphincterotomy could be performed easily with the guide wire (Figure 1). Endoscopic stone extraction can then be performed with the patient in the supine position.

Various endoscopic approaches to the treatment of CBD stones have been reported, including intraoperative endoscopic sphincterotomy by changing the position (1), left lateral laparoscopic cholecystectomy (2), temporary use of a biliary endoprosthesis during laparoscopic cholecystectomy (3), laparoscopic CBD exploration (4), and laparoscopic transcystic sphincterotomy under endoscopic control (5). We have also tried transcystic sphincterotomy, but it is not easy to rotate the papillotome into position to ensure a good cutting line. We therefore propose a simpler endoscopic sphincterotomy approach for the removal of CBD stones during laparoscopic cholecystectomy, as a normal endoscopic procedure. When a long guide wire is used, the technical difficulty of advancing a side-viewing endoscope and cannulating the sphincterotome can be overcome, even with the patient in the supine position.

H. Nakajima¹, H. Okubo¹, Y. Masuko¹, S. Osawa¹, K. Ogasawara¹, M. Kambayashi¹, Y. Hata¹, T. Oku¹, T. Takahashi²

¹ Dept. of Surgery, Kushiro Rosai Hospital, Kushiro, Japan;

² Dept. of Surgery, Kitasato University School of Medicine, Kitasato, Sagami-hara, Kanagawa, Japan

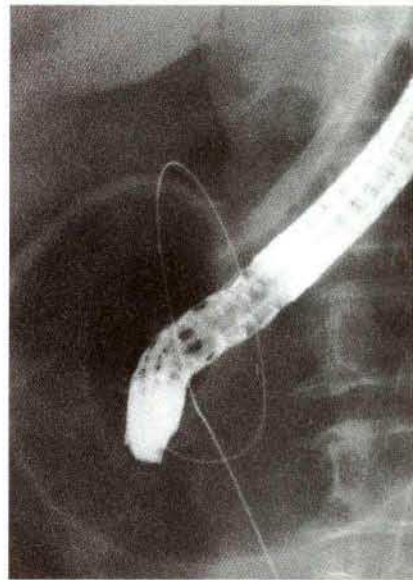


Figure 1: A side-viewing endoscope was advanced into the duodenum using a long guide wire, with the patient in the supine position.

References

1. Deslandres E, Gangner M, Pomp A, et al. Intraoperative endoscopic sphincterotomy for common bile duct stones during laparoscopic cholecystectomy. *Gastrointest Endosc* 1993; 39: 54-8.
2. Grieve DA, Merrett ND, Matthews AR, et al. Lateral laparoscopic cholecystectomy and its relevance to choledocholithiasis. *Aust NZ J Surg* 1993; 63: 715-8.
3. Rønning H, Raundahl U, Kiil J. Temporary use of a biliary endoprosthesis for unsuspected bile duct stones found at laparoscopic cholecystectomy. *Br J Surg* 1993; 80: 1443-4.
4. Zucker KA, Baily RW. Laparoscopic cholangiography and management of choledocholithiasis. In: Zucker KA, editor. *Surgical laparoscopy update*. St. Louis: Quality Medical, 1993: 145-93.
5. Feretis C, Kalliakmanis B, Benakis P, Apostolidis N: Laparoscopic transcystic papillotomy under endoscopic control for bile duct stones. *Endoscopy* 1994; 26: 697-700.

Corresponding Author

H. Nakajima, M.D.
Dept. of Surgery
Kushiro Rosai Hospital
13-23 Nakazono-cho
Kushiro 085
Japan
Fax: +81-01 54-25-73 08