

Colonoscopic Appearance of an Adenocarcinoid of the Vermiform Appendix

Adenocarcinoid tumors of the vermiform appendix are very rare malignancies (1), which share the histological features of both carcinoids and adenocarcinomas (2) and are rarely diagnosed before surgery (3).

A 60-year-old man was admitted due to abdominal pain in the right lower quadrant, vomiting, and abdominal distension. Physical examination revealed moderate painful tenderness, with no rebound in the right lower quadrant. Blood studies showed leukocytosis ($17,800/\text{mm}^3$). Emergency plain radiography of the abdomen showed dilated small bowel loops. After 24 hours of conservative treatment, the patient was asymptomatic, and the abdominal radiographs and white cell count became normal. Colonoscopy was carried out, and a submucosal umbilicated mass of about 3 cm in diameter was found in the cecum, located opposite to the ileocecal valve, with normal-looking mucosa (Figure 1). The patient underwent surgery, and a 9-cm tumoral mass was found, involving the cecum, vermiform appendix, terminal ileum, and mesentery. Histological examination of the surgical specimen showed a large appendiceal primary malignant tumor, and a diagnosis of appendiceal adenocarcinoid was made.

Adenocarcinoid of the vermiform appendix is a separate entity from adenocarcinoma and carcinoid tumors (4), and may originate from a unique cell line, probably from crypt-based stem cells (3, 5). Adenocarcinoids show a concentration of neoplastic elements around the basiglandular portion of the mucosa, as do conventional carcinoids. In contrast to adenocarcinoma, the mucosa is free of malignant changes (5), which may explain the submucosal endoscopic appearance of the tumor.

Adenocarcinoids are more aggressive than the typical carcinoid. Perineural and lymphatic invasion is common, and there is often a propensity for local spread (3). Right colectomy is the best treatment when the tumor is large and has invaded the surrounding organs, as in the present case.

F. J. Jiménez-Pérez, A. Echarri, F. Borda
Endoscopy Unit, Hospital de Navarra, Pamplona, Spain

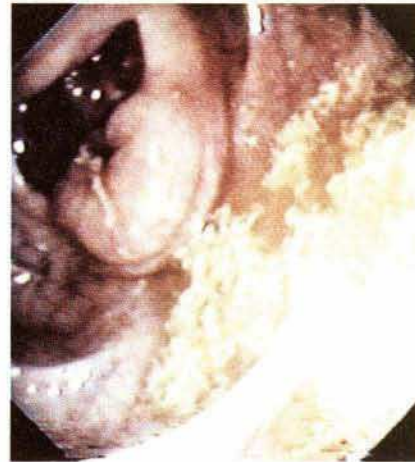


Figure 1: A submucosal umbilicated mass in the cecum, located opposite to the ileocecal valve.

References

1. Edmonds P, Merino MJ, Livolsi A, et al. Adenocarcinoid (mucinous carcinoid) of the appendix. *Gastroenterology* 1984; 86: 302–9.
2. Bak M, Asschenfeldt P. Adenocarcinoid of the vermiform appendix: a clinicopathologic study of 20 cases. *Dis Colon Rectum* 1988; 31: 605–12.
3. Rutledge RH, Alexander JW. Primary appendiceal malignancies: rare, but important. *Surgery* 1992; 111: 244–50.
4. Park K, Blessing K, Kerr K, et al. Goblet cell carcinoid of the appendix. *Gut* 1990; 31: 322–4.
5. Berardi RS, Lee SS, Chen HP. Goblet cell carcinoids of the appendix. *Surg Gynecol Obstet* 1988; 167: 81–6.

Corresponding Author
F.J. Jiménez-Pérez, M.D.
Endoscopy Unit
Hospital de Navarra
c/ Irunlarrea 3
31008 Pamplona
Spain
Fax: +34-948-102303