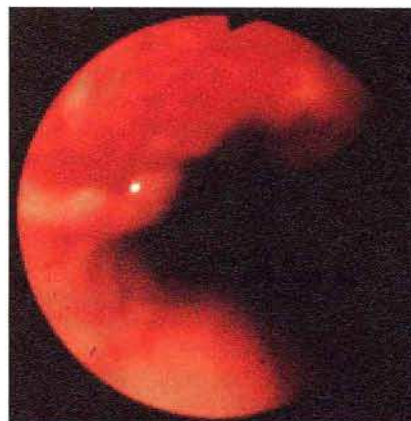


### Idiopathic Esophageal Ulceration Associated with Human Immunodeficiency Virus Infection: Efficacy of Thalidomide Treatment

A 30-year-old man was infected by HIV in 1983 during splenectomy following an abdominal stabbing incident. In November 1993 (CD4 cell count: 25/mm<sup>3</sup>), the patient presented with severe dysphagia for solids. An empirical trial of ketoconazole was started, but one week later, chest pain and dysphagia for fluids appeared. A giant solitary ulcer was found at endoscopy in the middle esophagus (25 mm in maximum diameter). Intravenous antiviral treatment was started (acyclovir and ganciclovir). However, biopsy samples from the edge of the ulcer showed only nonspecific inflammation, and the cell culture, immunofluorescent staining, and molecular DNA probes for CMV and HSV failed to show any viral particles. Five days after the start of antiviral treatment, no clinical improvement was observed. A new endoscopy showed an extension of the ulceration (Figure 1). All treatment was therefore stopped, and the large ulceration was considered to be idiopathic. Thalidomide treatment at 100 mg daily was initiated, and the patient was asymptomatic five days later (total course of thalidomide: one month). In May 1995, no recurrence was observed.

Esophageal diseases are common in HIV-infected patients (1). However, there have so far only been a few reports of idiopathic esophageal ulceration. These lesions are generally solitary, large, frequently painful, and often located in the mild or distal



**Figure 1:** Endoscopic image of the idiopathic esophageal ulceration.

esophagus. They can mimic the other causes of ulcerative esophagitis, and should not be considered idiopathic until a thorough histopathological examination of the ulcer has been performed and, peptic or drug-induced esophagitis, neoplastic, or infectious causes have been excluded (2). Therapy for idiopathic ulceration of the esophagus is poorly defined. Increasing experience with oral or intravenous corticosteroid therapy suggests amelioration of pain, but recurrent symptoms are frequent (3). Intralesional injections of corticosteroids have been proposed (4). In AIDS patients, corticosteroid therapy could have immunologic and virologic effects (3). Thalidomide is successfully used for resistant aphthous ulceration in AIDS patients, but its mechanism

of action remains unclear (5). Thalidomide should be tested as an alternative therapy to corticosteroids in patients with idiopathic ulceration of the esophagus occurring in AIDS.

*D. Louvel<sup>1</sup>, S. Musso<sup>1</sup>, S. Métivier<sup>1</sup>, O. Croizet<sup>1</sup>, R.-M. Rouquet<sup>2</sup>, P. Massip<sup>3</sup>, J. Escourrou<sup>1</sup>, J. Frexinos<sup>1</sup>*

<sup>1</sup> Gastroenterology Unit, Centre Hospitalier Universitaire Rangueil, Toulouse, France

<sup>2</sup> Pneumology Unit, Centre Hospitalier Universitaire Rangueil, Toulouse, France

<sup>3</sup> Dept. of Infectious Diseases, Centre Hospitalier Universitaire Rangueil, Toulouse, France

## References

1. Wilcox CM. Esophageal disease in the acquired immunodeficiency syndrome: etiology, diagnosis, and management. *Am J Med* 1992; 92: 412–21.
2. Wilcox CM, Schwartz DA. Endoscopic characterization of idiopathic esophageal ulceration associated with human immunodeficiency virus infection. *J Clin Gastroenterol* 1993; 16: 251–6.
3. Wilcox CM, Schwartz DA. A pilot study of oral corticosteroid therapy for idiopathic esophageal ulceration associated with human immunodeficiency virus infection. *Am J Med* 1992; 93: 131–4.
4. Kotler DP, Peka S, Borcich A, Winkler WP. Corticosteroid therapy of idiopathic esophageal ulcers in AIDS. *Gastrointest Endosc* 1990; 36: 191–2.
5. Youle M, Clarbour J, Farthing C, et al. Treatment of resistant aphthous ulceration with thalidomide in patients positive for HIV antibody. *Br Med J* 1989; 298: 432.

## Corresponding Author

D. Louvel, M. D.

Gastroenterology Unit

Centre Hospitalier Universitaire Rangueil

31054 Toulouse

France

Fax: +33-61322229