

Fibrolipoma of the Colon with an Unusual Appearance

A 52-year-old man came to our hospital for further evaluation of hematochezia. The endoscopic examination demonstrated a slender polyp, 8–9 cm long, in the ascending colon (Figure 1). The tip of the polyp was club-shaped, and it had a smooth surface. Inserting the endoscope further, we could see that the base was at the cecum. There were also two small polyps in the cecum. The slender polyp was snared at its middle portion and resected by electrocautery. The resected specimen was 5 cm long and 1 cm in

diameter. The pathological examination revealed that the tumor, located in the submucosa, was composed of matured adipose tissue with a proliferation of fibrous connective tissue and dilated vessels (Figure 2). These findings were consistent with fibrolipoma.

Lipoma is the commonest benign nonepithelial tumor of the colon (1). It is further subclassified by the proportion of other mesenchymal components constituting the inner part. The type that is rich in fibrous components is termed “fibrolipoma” (2), and it is a very rare condition (3). In Japan, there have been only two reported colonic cases (4). The etiology of fibrolipoma is generally considered to be chronic mechanical irritation or inflammation

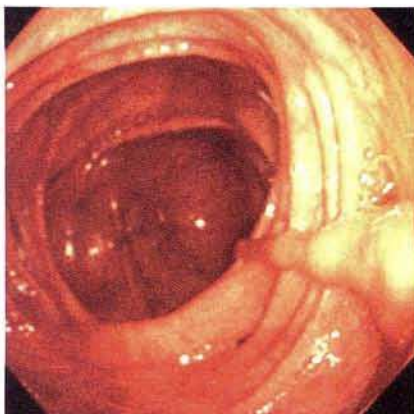


Figure 1: A slender polyp, 8–9 cm long, resembling an earthworm, was found in the ascending colon. The tip of the polyp was club-shaped, and the base was at the cecum.

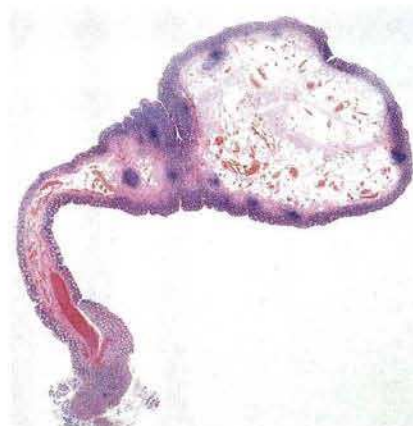


Figure 2: A cross-section of the tumor, showing the fibrous component in the matured adipose tissue (hematoxylin-eosin, original magnification $\times 1$).

that induces secondary fibrous changes in the lipoma (4). The two other Japanese cases were both pedunculated, larger than 4cm in diameter, and accompanied by intussusception, while in our case the fibrolipoma was small in diameter and without intussusception. We assume, however, that some type of inflammation in the cecum was involved in the formation of these polyps and causing the fibrous change in the lipoma, since the two small polyps were also confirmed as inflammatory on biptic histology. Although there was no difficulty with the endoscopic polypectomy in this case, great care is needed due to the risk of perforation in lipomas that are larger than 2cm in diameter and have a limited pedicle (5).

*H. Yoshikane, H. Hidano, A. Sakakibara, T. Ayakawa,
M. Watanabe, A. Takeuchi, S. Hashimoto, S. Mori*
Dept. of Internal Medicine, Handa City Hospital, Handa, Japan

References

1. Stout AP. Tumors of the colon and rectum (excluding carcinoma and adenoma). *Surg Clin North Am* 1955; 35: 1283–8.
2. Enzinger FM, Weiss SW. Benign lipomatous tumors. In: *Soft tissue tumors*. St. Louis: Mosby, 1988: 305.
3. Mayo CW, Pagtalunan RJG, Brown DJ. Lipoma of the alimentary tract. *Surgery* 1963; 53: 598–603.
4. Kawamoto K. Fibrolipoma of the intestine [in Japanese]. In: Jomei T, editor. *Syndromes of the gastrointestinal tract*. Osaka: Nippon Rinsho, 1994: 502–4.
5. Pfeil SA, Weaver MG, Abdul-Karim FW, et al. Colonic lipomas: outcome of endoscopic removal. *Gastrointest Endosc* 1990; 36: 435–8.

Corresponding Author

H. Yoshikane, M.D.
Dept. of Internal Medicine
Handa City Hospital
2–29 Toyo-cho
Handa
Aichi
Japan
Fax: +81-569-24-3253