Extensive Oesophageal Haematoma with Haematemesis Treated by Sclerosant Injections

A 79-year-old, previously healthy, woman was admitted with severe haemetemesis, chest and epigastric pain, and odynophagia. She had been taking aspirin, 300 mg daily, for three weeks as she thought this was good for her health. Her haemoglobin dropped from 11.8 gm/dl to 9.7 gm/dl, and hypotension requiring intravenous fluids developed. Her chest radiograph, upper abdominal ultrasound, platelet count and coagulation studies were all normal. Emergency endoscopy revealed haematoma longitudinally down the whole oesophagus (Figure **1**), with active bleeding in its lower part, but no visualized tear. Sodium tetradecyl sulphate was injected round the bleeding area, and the bleeding stopped. A repeat endoscopy one week later showed sloughed tissue along the oesophagus, following the distribution of the previously seen haematoma (Figure **2**). A 2-cm piece of tissue came out with the endoscope, showing thrombus with no vessel wall on histology. The patient made a full recovery, and was discharged. A further endoscopy four weeks later showed only a small scarred area at the site of previous bleeding, with normal remaining mucosa.

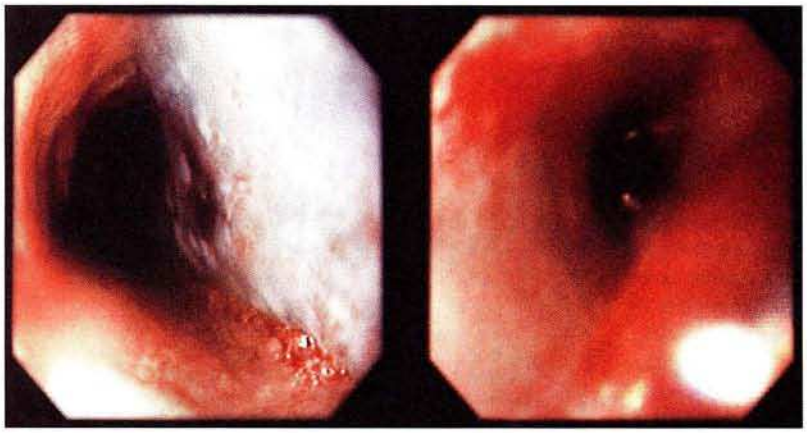

Figure 1: Oesophageal haematoma at presentation.

Figure 2: Tissue sloughing in oesophageal haematoma, one week after presentation.

This document was downloaded for personal use only. Unauthorized distribution is strictly prohibited.

Although a mucosal tear was not visualized, such a tear resulting from vomiting, producing a variation of the Mallory-Weiss syndrome (1), is the likely cause of the oesophageal haematoma and haemetemesis in this patient. The natural course of oesophageal haematoma is complete resolution, and it is usually treated conservatively if oesophageal perforation is excluded (2). It is debatable to what extent the sclerosant injections contributed to stopping the bleeding in this case.

References

1. *Watts HD:* Postemetic hematomas: a variant of the Mallory-Weiss syndrome. Am J Surg 1976; 132: 320–321.
2. *Kerr WF:* Spontaneous intramural rupture and intramural haematoma of the oesophagus. Thorax 1990; 35: 890–897.

Corresponding Author
F. S. S. Alani, M.D.
Department of Medicine
Blackburn Royal Infirmary
Blackburn BB2 3LR
United Kingdom

This document was downloaded for personal use only. Unauthorized distribution is strictly prohibited.