Small-Bowel Necrosis Following Laparoscopic Cholecystectomy: a Clinically Relevant Complication?

A 65-year-old woman presented with right upper quadrant abdominal pain after a ten-year history of cholecystolithiasis. Preoperative ultrasound studies showed numerous gallbladder stones of varying size and nondilated bile ducts.

During a 90-minute laparoscopic cholecystectomy, multiple adhesions and inflammatory tissue in the area of the infundibulum and the cystic duct were removed using electrocautery. After this, an intraoperative cholangiogram was normal. The procedure was terminated laparosocopically without any further complications.

On the second postoperative day, the patient complained of bilateral upper quadrant abdominal pain radiating to the back. This was accompanied by leukocytosis (13.100/ml) and a rise in serum bilirubin (2.98 mg/dl). Endoscopic retrograde cholangiopancreatography (ERCP) on the third postoperative day showed endoscopically a swollen papilla of Vater with numerous necrotic areas measuring about 3–4 cm in diameter in the duodenal bulb and descending duodenum (Figure 1). After therapy with antacids and antibiotics, laboratory findings returned to normal within four days. A control gastroduodenoscopy after two weeks showed complete healing of the necrotic areas, partially with scars.

In contrast to the bipolar technique, monopolar techniques used for coagulation and electrotomy can cause aberrant currents directed toward the neutral electrode (1–3). It was speculated that this mechanism may cause extensive tissue necrosis and lead to iatrogenic functional stenosis (4). The appearance of extensive adhesions and scar tissues at the site of surgery can predict the risk of injuries due to an uncontrolled and overlong duration of current flow and tissue resistance. Bipolar high-frequency techniques are preferable in such cases.

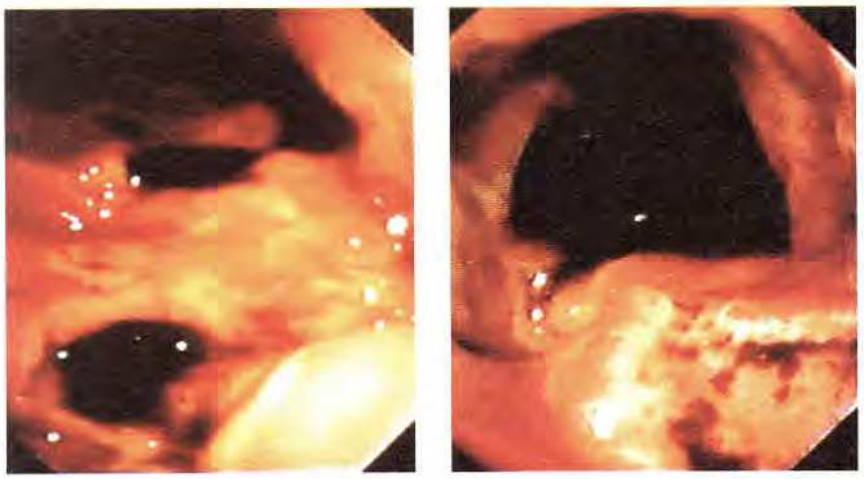

Figure 1 a, b: Side-viewing endoscopy, showing a swollen papilla and multiple areas of deep necrosis in the descending duodenum. The ERCP showed a slightly dilated bile duct without stones, and a normal pancreatic duct.

References

1. *Kühner W:* Endoskopische Hochfrequenz-Diathermie-Anwendungen: Polypektomie-Sphinkterotomie (Papillotomie). Leber Magen Darm 1985; 15: 227–231.
2. *Tucker RD, Sievert CE, Kramolowsky EV,* et al.: The interaction between electrosurgical generators, endoscopic electrodes, and tissue. Gastrointest Endosc 1992; 38: 118–122.
3. *Tucker RD, Sievert CE, Platz CE,* et al.: Bipolar electrosurgical sphincterotomy. Gastrointest Endosc 1992; 38: 112–117.
4. *Riedel HH, Cordts-Kleinwort G, Semm K:* Tierexperimentelle, morphologische und endokrinologische Untersuchungen nach Anwendung verschiedener Koagulationstechniken. Zentralbl Gynäkol 1983; 105: 1568–1584.

D. Hebebrand, R. Menningen, H. Sommer, S. P. Roehr, H. Troidl
Second Depatment of Surgery, University of Cologne, Cologne, Germany

Corresponding Author:
D. Hebebrand, M.D.
Department of Surgery
UCLA School of Medicine
CHS 61-141
10833 Le Conte Avenue
Los Angeles, CA 90024
U. S. A.