

Combined Hydrostatic and Pneumatic Balloon Dilatation of the Post-Gastrectomy "Hourglass" Stomach

Dilatation of stenoses of the gastric outlet and of gastroenterostomy stomas using hydrostatic through the scope (TTS) balloons is well established. We describe a technique, which we have not seen described previously, of sequential hydrostatic/pneumatic balloon dilatation for more proximal "hourglass" postgastrectomy strictures. In our first case, a 53-year-old woman experienced weight loss, epigastric pain, and vomiting and was unresponsive to medical therapy. Five years previously a highly selective vagotomy for duodenal ulcer was performed followed two years later by a Billroth I gastrectomy for a benign incisural ulcer. Gastroscopy showed solid residue proximal to a 4 mm stenosis with ulceration, thought initially to be at the outlet. However, TTS balloon (Microvasive) dilatation allowed endoscope advancement to confirm that the antrum and true outlet (also stenosed and requiring dilatation) lay beyond. Over the next three years, prompted by symptom recurrence, she had six dilatations of the proximal stenosis with 15, 18 and 20 mm hydrostatic TTS balloons. One month after the last procedure, we opted to perform elective dilatation using a 20 mm TTS balloon (Figure 1). Before removal, the endoscope was used to place a wire under fluoroscopic guidance. A 30 mm pneumatic achalasia balloon (Microvasive) was then passed along the wire to cross the stricture, again guided by fluoroscopy, and inflated. Pressure was maintained until "waisting" of the balloon caused by the stricture (Figure 2) vanished. She had no complications and has been symptom-free for 12 months on medical therapy. Repeat endoscopy shows continuing ulcer activity but no restenosis.

In the second case, a 50-year-old man presented with intractable vomiting, regurgitation, and epigastric pain. Two years previously he had undergone truncal vagotomy and gastroenterostomy with wide excision of a benign lesser-curve ulcer. A barium meal showed luminal constriction well proximal to the stoma. Gastroscopy confirmed a stricture at this site, which was dilated using an 18 mm hydrostatic TTS balloon; the stoma itself was not stenosed. One month later, because of persisting symptoms, he had further dilatation with a 20 mm TTS balloon followed by the wire-guided 30 mm achalasia balloon as described above. Again, he had no complications and after 20 months remains symptom-free on medical therapy.

Both cases demonstrated developed strictures at the site of previous resection, despite vagotomy. Hydrostatic balloon dilatation is effective for the stenosed outlet, but a greater degree of dilatation, for "physiological" purposes, is probably required for more proximal stricturing. Sequential dilatation, using hydrostatic TTS balloons followed by the pneumatic achalasia balloon achieves this safely and effectively.

W. Dickey, K. G. Porter

Department of Gastroenterology, Belfast City Hospital
Department of Medicine, Queen's University of Belfast,
Northern Ireland, United Kingdom

Corresponding Author

W. Dickey M.D.
Department of Medicine
Institute of Clinical Science
Grosvenor Road
Belfast BT12 6BJ
United Kingdom

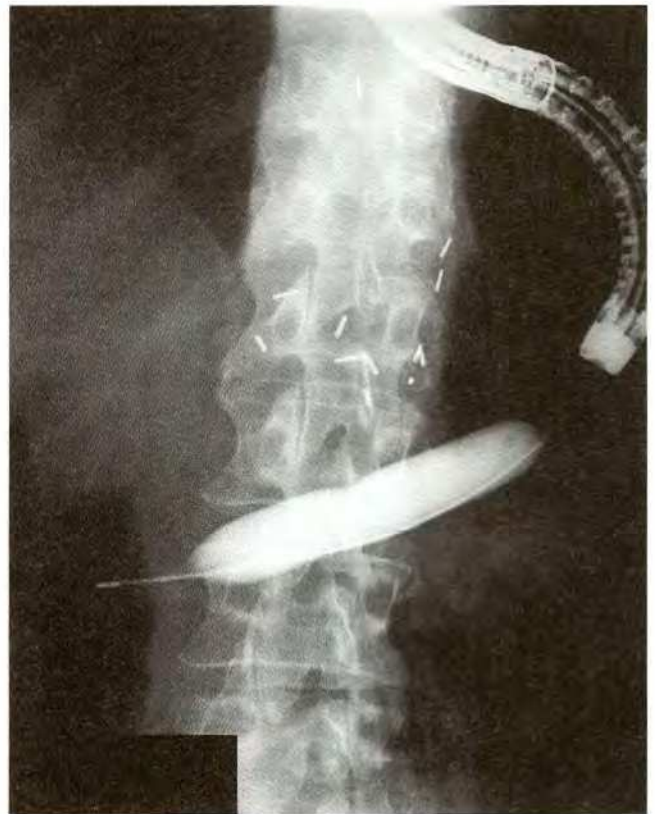

Figure 1: Gastric stricture causing "waisting" of a 20 mm Microvasive TTS hydrostatic balloon during dilatation.

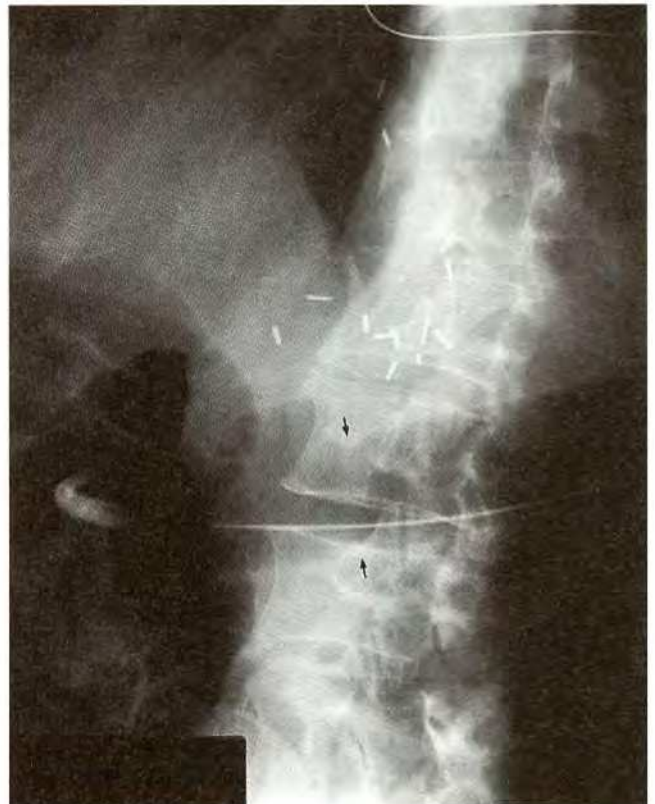


Figure 2: Case 1; Following hydrostatic balloon dilatation, a pneumatic achalasia balloon is passed under fluoroscopic guidance and used for further dilatation ("waisting" arrowed).