

Frequent Submucosal Migration of Soft Percutaneous Endoscopic Gastrostomy Catheters, and Conservative Management

Migration of percutaneous endoscopic gastrostomy (PEG) tubes may occur after 1–4% of tube insertions (1, 2, 3). In four out of eleven patients treated at our hospital in whom a soft silicone type of PEG catheter (MIC-KEY) was inserted using the pull technique (4), the inner bolster of the device dislocated into the submucosa. In all four patients, the PEG tube was placed before surgery and radiotherapy for oropharyngeal cancer. In one patient, the tube migrated into the gastric submucosa two days after the PEG procedure, and could be removed endoscopically by grasping the inner bolster rim with a large forceps. In the three other patients, the PEG tube migrated submucosally after 1–4 months. They had all gained considerable weight through a period of tube feeding. PEG migration was attended in one patient with obstruction of the tube.

Two other cases of tube dislocation were discovered accidentally during oncological survey endoscopy. In two of these patients, the PEG device could not be reached by a forceps, and had to be removed nonendoscopically, using only external traction with a load of 250 grams over 24 hours (Figure 1). No complications were seen afterwards.

Despite the small numbers of patients described here, it can be stated that the fairly frequent submucosal migration of MIC-KEY PEG devices may be due to the soft silicone material they consist of. We did not see this complication in 153 patients who obtained a Freka type of catheter, which is made of polyurethane and has a solid inner bolster.

J. D. van Bergeijk, C. J. J. Mulder

Department of Hepatogastroenterology, Rijnstate Hospital, Arnhem, The Netherlands

References

1. Larson DE, Burton DD, Schroeder W, Di Magno EP: Percutaneous endoscopic gastrostomy: indications, success, complications and mortality in 314 consecutive patients. *Gastroenterology* 1987; 93: 48–52.

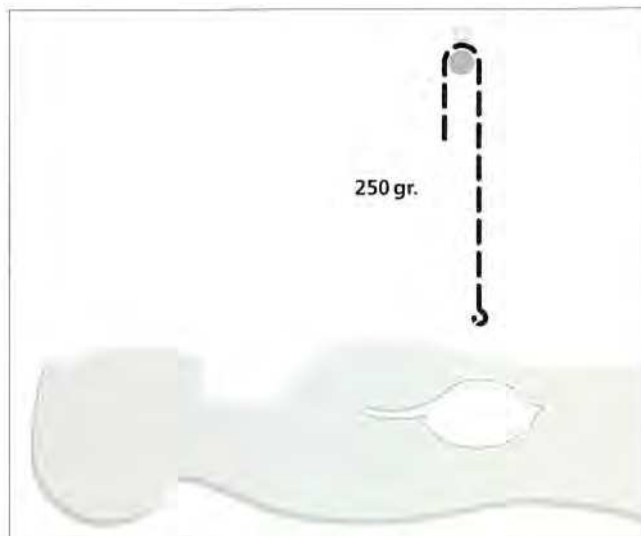


Figure 1: Removal of a dislocated PEG tube under traction.

2. Ponsky JL, Gauderer MWL, Stellato TA: Percutaneous endoscopic gastrostomy: review of 150 cases. *Arch Surg* 1983; 118: 913–914.
3. Kadakia LTCSC, Sullivan HO, Starnes E: Percutaneous endoscopic gastrostomy or jejunostomy and the incidence of aspiration in 79 patients. *Am J Surg* 1992; 164: 114–118.
4. Gauderer MWL, Ponsky JL, Izant RJ: Gastrostomy without laparotomy: a percutaneous endoscopic technique. *J Pediatr Surg* 1980; 15: 872–875.

Corresponding Author

C. J. J. Mulder, M.D.
Department of Hepatogastroenterology
Rijnstate Hospital
P.O. Box 9555
6800 AT Arnhem
The Netherlands
Fax No: 31 85 529275