A Clear Diagnosis of Intussusception of the Appendix

K. M. Reddy, M. J. Lamparelli, S. S. Mudan, R. J. Leicester, M. J. Knight

Department of Surgery, St. George's Hospital, London, UK

Corresponding Author

M. J. Knight, M.S., F.R.C.S.
Consultant Surgeon
St. George's Hospital
London SW170 QT
UK
Fax: + 44-181-672-8114

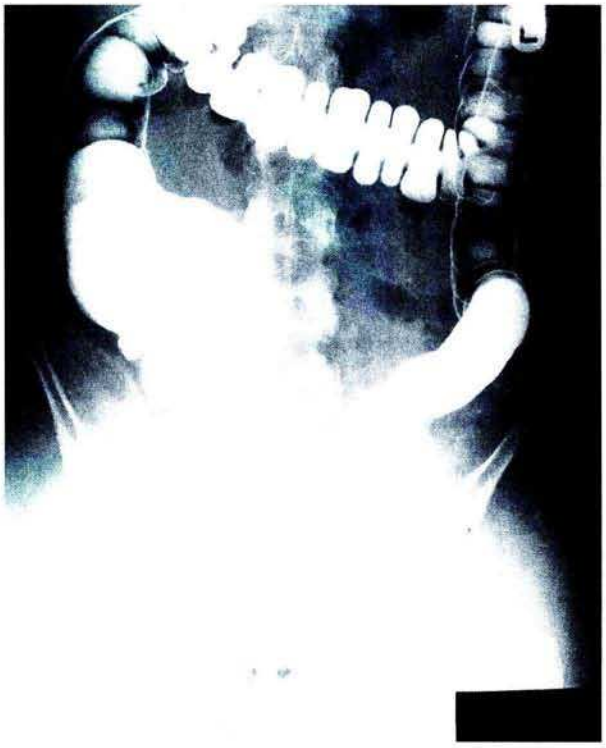

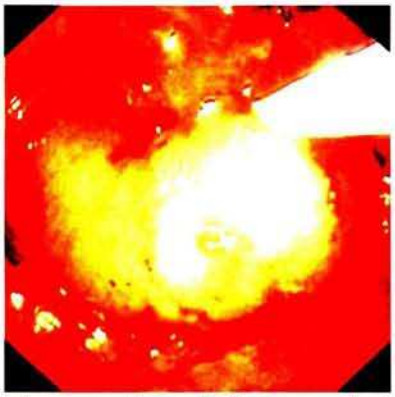

Intussusception of the appendix is a rare condition (0.01 % of specimens) which can cause diagnostic difficulty, and lead to prolonged investigation of vague abdominal symptoms. Non-filling of the appendix and a coiled appearance at the caecum is suggestive of the diagnosis. In this young women, a barium enema showed a caecal polyp (Figure **1**), but the correct diagnosis of appendiceal intussusception was made by colonoscopy (Figure **2**), obviating further investigation. The specimen contained a focus of endometriosis.

This document was downloaded for personal use only. Unauthorized distribution is strictly prohibited.