Laparoscopy-Controlled Suture Closure of Large Stab Wounds

Minimally invasive surgery is still an expanding field in general surgery. In abdominal laparoscopic procedures, large trocars are routinely used. This may result in incisional hernias, with consecutive incarceration. In one of our initial cases of laparoscopic herniorrhaphy, the small bowel incarcerated at the site of a 12-mm trocar wound. At the time, we closed the fascia only externally, and not under videolaparoscopic vision. To our knowledge, there have so far been no publications on incarceration of the small bowel at trocar wounds. Nevertheless, the problem was discussed at the 5th International Meeting of the Society for Minimally Invasive Therapy, Orlando, USA. We therefore think that hernia formation is not a single incident, and an awareness of the possibility of incarceration of the small bowel might help to avoid this problem. In 1984, Semm (1) recommended that the fascia at sites larger than 10 mm trocars should be closed by sutures to avoid hernia formation.

Closure of small incisions such as those used in minimally invasive therapy may sometimes confront the surgeon with a challenge. To ease this problem, we have developed a laparoscopy-controlled method for closure of the fascia with a straight suture holder (WISAP) and 1-0-vicryl. As an extra benefit, the stab wound is immediately airtight, and this technique (Figures **1**, **2**) is equally suitable for controlling bleeding from trocar wounds. Bleeding from trocar incisions is another serious complication of minimally invasive therapy (2). Laparoscopy-controlled suture closure of large stab wounds is an easy and safe technique, mainly in obese patients, to avoid hernia formation and to control bleeding.

K. Miller, J. Hutter, A. Amerhauser
Second Surgical Department, Landeskrankenanstalten Salzburg, Salzburg, Austria

References

1. *Semm K:* Operationslehre für endoskopische Abdominal-Chirurgie. Stuttgart: Schattauer, 1984.
2. *Schumpelick V, Schippers E, Kupcyk-Joeris D:* Fehler und Gefahren in der Hernienchirurgie. Chirurg 1993; 64: 237–243.

Corresponding Author
Karl Miller, M.D., Second Surgical Department, Landeskrankenanstalten Salzburg, Müllner Hauptstrasse 48, 5020 Salzburg, Austria

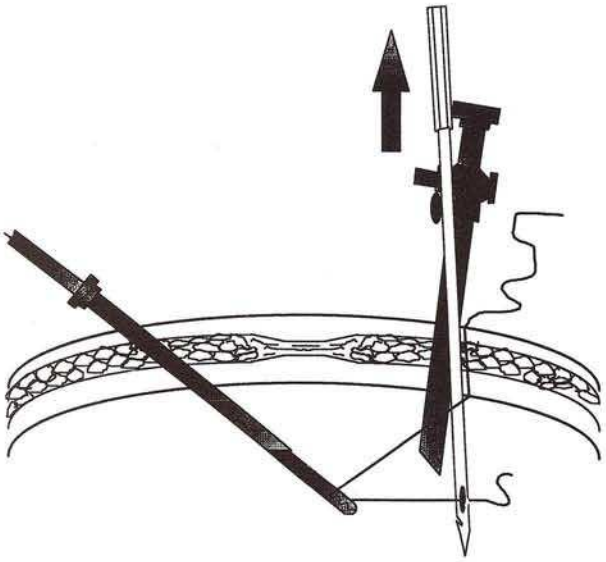

Figure 1: The straight suture holder, with the suture threaded into the holder, is pased through the abdominal wall beside the trocar. The suture is grasped internally with a forceps before the suture holder is withdrawn.

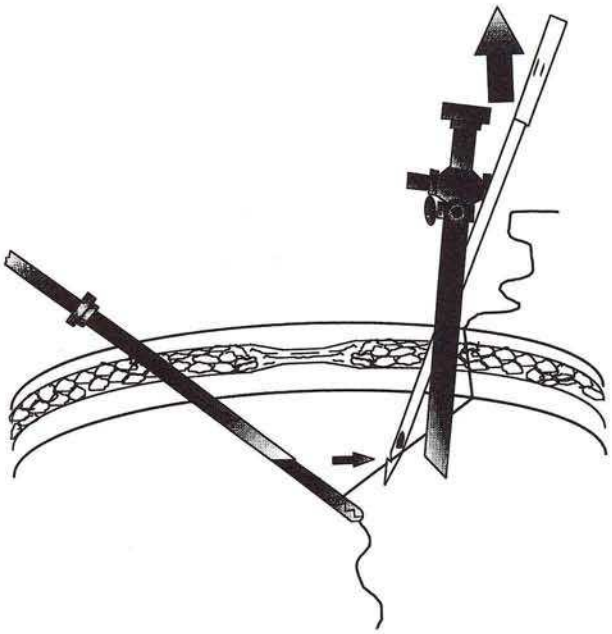

Figure 2: The straight unloaded sutureholder is reinserted on the opposite side of the trocar, and the suture is threaded through the notch and exteriorized. The trocar is now removed, and the two ends of the suture are pulled tight and tied.

This document was downloaded for personal use only. Unauthorized distribution is strictly prohibited.