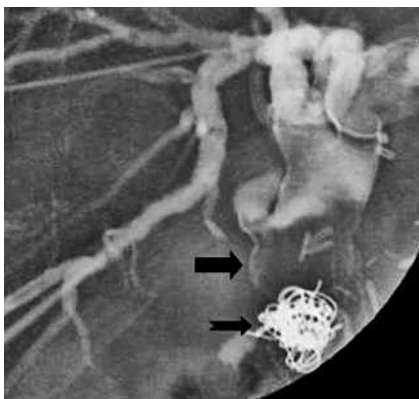
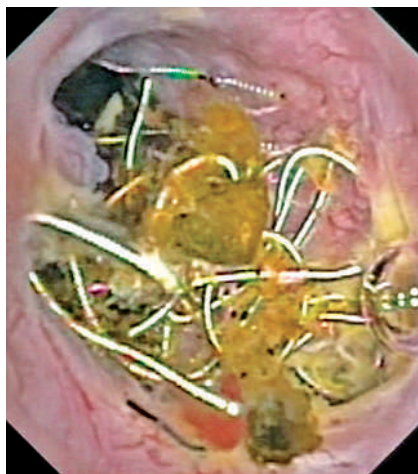


## Successful percutaneous cholangioscopic extraction of vascular coils that had eroded into the bile duct after liver transplantation



**Figure 1** Percutaneous transhepatic cholangiographic view showing a large impacted stone in the common hepatic duct (arrow), proximal to a cluster of metallic wires (indented arrow). These wires corresponded to the previously inserted vascular microcoils, which had eroded and migrated into the bile duct.



**Figure 2** After progressive dilatation of the percutaneous transhepatic track, percutaneous cholangioscopy was performed, yielding a direct view of the cluster of vascular coils. All the coils were successfully removed via the percutaneous track using a biopsy snare.

Bleeding into the bile duct from a hepatic artery pseudoaneurysm is a rare complication of liver transplantation [1–4] which can be treated by transcatheter coil embolization. Biliary coil erosion after pseudoaneurysm embolization has been reported only once before, and the treatment in that case consisted of surgical choledochotomy [5]. We present a patient who underwent coil embolization of a bleeding pseudoaneurysm after transplantation, in whom coils were later found to have migrated into the bile duct. Surgery was avoided in this patient by removal of the coils by percutaneous cholangioscopy.

A 72-year old patient was admitted in July 2005 with biliary colic. In 2002 he had undergone liver transplantation because of primary biliary cirrhosis. Arterial reperfusion was achieved by end-to-end arterial anastomosis, and biliary reconstruction by duct-to-duct anastomosis. On day 73 after the transplantation he developed a gastrointestinal bleed caused by rupture of a hepatic artery anastomotic pseudoaneurysm, which was treated by packing with microcoils. The bleeding recurred and angiography showed revascularization of the pseudoaneurysm and a hepatic artery anastomotic stenosis. A balloon-expandable ePTFE-covered cor-

onary stent graft was inserted into the hepatic artery to exclude the pseudoaneurysm from the circulation [1]. The clinical course was then uneventful until the biliary colic developed.

Endoscopic retrograde cholangiopancreatography was unsuccessful. Percutaneous transhepatic cholangioscopy was performed, when the vascular coils were noted to be close to the bile duct, with a biliary stone proximal to the coils (● **Figure 1**). After maturation of the percutaneous track, a video bronchoscope (160BF; Olympus, Tokyo, Japan) was inserted into the biliary system. As well as the stone, a clow of metallic wires was observed (● **Figure 2**). The stone was removed by electrohydraulic lithotripsy. Because the coils, which had apparently migrated from the pseudoaneurysm into the bile duct, could act as a cause of recurrent stone formation, it was decided to remove them via the percutaneous track, and these were successfully cleared from the bile duct (**Video 1**). The patient was discharged 2 days after the procedure, and has remained asymptomatic since.

Endoscopy\_UCTN\_Code\_TTT\_1AR\_2AJ

### Video 1

On entering the bile duct by percutaneous cholangioscopy, and after removal of the stone by electrohydraulic lithotripsy, a cluster of vascular coils that had migrated from the hepatic artery pseudoaneurysm into the bile duct was seen. All the coils were grasped and removed one by one using a biopsy snare, without any sign of bleeding from the arterio-biliary fistula. By the end of a second cholangioscopic procedure, the eroded coils had been completely cleared from the bile duct system.

**online content including video sequences viewable at:**

[www.thieme-connect.de/ejournals/abstract/endoscopy/doi/10.1055/s-2007-966314](http://www.thieme-connect.de/ejournals/abstract/endoscopy/doi/10.1055/s-2007-966314)

**W. Van Steenberg<sup>1</sup>, K. Lecluyse<sup>1</sup>, G. Maleux<sup>2</sup>, J. Pirenne<sup>3</sup>**

<sup>1</sup> Unit for Liver, Biliary, and Pancreatic Diseases, Department of Internal Medicine, University Hospital Gasthuisberg, Catholic University of Leuven, Leuven, Belgium

<sup>2</sup> Department of Radiology, University Hospital Gasthuisberg, Catholic University of Leuven, Leuven, Belgium

<sup>3</sup> Liver Transplantation Unit, Department of Abdominal Surgery, University Hospital Gasthuisberg, Catholic University of Leuven, Leuven, Belgium

## References

- 1 *Maleux G, Pirenne J, Aerts R, Nevens F.* Hepatic artery pseudoaneurysm after liver transplantation: definitive treatment with a stent-graft after failed coil embolisation. *Br J Radiol* 2005; 78: 453–456
- 2 *Millonig G, Graziadei IW, Waldenberger P et al.* Percutaneous management of a hepatic artery aneurysm: bleeding after liver transplantation. *Cardiovasc Intervent Radiol* 2004; 27: 525–528
- 3 *Riedmann B, Pernthaler H, Konigsrainer A et al.* Life-threatening gastrointestinal bleeding after liver transplantation due to hepatic artery pseudoaneurysm perforating into the common bile duct: a case report. *Transpl Int* 1995; 8: 492–495
- 4 *Marshall MM, Muiesan P, Srinivasan P et al.* Hepatic artery pseudoaneurysms following liver transplantation: incidence, presenting features and management. *Clin Radiol* 2001; 56: 579–587
- 5 *Ozkan OS, Walser EM, Akinci D et al.* Guglielmi detachable coil erosion into the common bile duct after embolization of iatrogenic hepatic artery pseudoaneurysm. *J Vasc Interv Radiol* 2002; 13: 935–938

## Bibliography

**DOI** 10.1055/s-2007-966314  
*Endoscopy* 2007; 39: E210–E211  
© Georg Thieme Verlag KG Stuttgart · New York ·  
ISSN 0013-726X

## Corresponding author

**W. Van Steenberghe, MD**  
Unit for Liver, Biliary, and Pancreatic Diseases  
Department of Internal Medicine  
University Hospital Gasthuisberg  
3000 Leuven  
Belgium  
Fax: +32-16-344387  
Werner.vansteenbergen@uz.kuleuven.be