

Acute parotiditis and facial nerve palsy – unusual side effects of Xylocaine spray

Xylocaine (lidocaine) is the most commonly used agent for local surface anesthesia. The adverse effects of Xylocaine are more common with intravenous injections or rapid injections than with surface anesthesia. We present a case of a 52-year-old white English woman who underwent upper gastrointestinal endoscopy for dyspepsia.

The patient was premedicated with five sprays of Xylocaine (10 mg/spray) in the throat. Endoscopy was successfully carried out, with the patient in the left lateral position, by a trainee on a course under direct supervision. After 30 minutes, the patient complained of pain and numbness in the left-upper neck, and difficulties with speech. Examination revealed mild tenderness in the left upper part of the neck, and lower motor neuron palsy of the mandibular and cervical branches of the facial nerve. An urgent ultrasound scan revealed acute left parotiditis with no ductal dilatation.

After 4 hours of observation, the pain disappeared completely, and the patient regained normal speech. The tenderness and manifestations of facial nerve palsy disappeared. She was discharged from the endoscopy unit.

Here, we report transient acute parotiditis and facial nerve palsy as possible complications of Xylocaine spray. We believe that the left-lateral position of the patient (or spraying onto the left buccal mucosa rather than into the back of the throat) allowed the accumulation and subsequent absorption of lidocaine, thus causing these complications.

Facial palsy may be due to nerve blockade effects, and acute parotiditis may be due to hypersensitivity. These complications are documented with lidocaine in surface and regional anesthesia but not with a

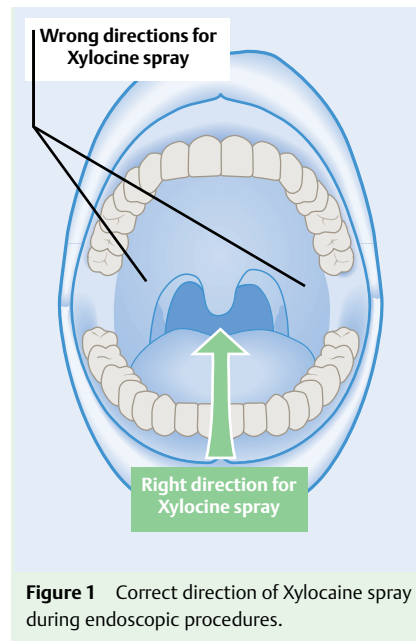


Figure 1 Correct direction of Xylocaine spray during endoscopic procedures.

spray [1–3]. Acute parotiditis has been reported following general anesthesia and oral endoscopy, and termed “anesthesia mumps” [4], where parotiditis is thought to be related to trauma [5] from positioning of the endoscope or transient luxation of the temporomandibular joint. We cannot ignore the possibility that this may have been caused by the incorrect handling of the endoscope by the trainee. In this context, acute parotiditis itself may cause facial palsy. We recommend using lidocaine spray in the proper position and direction (● **Figure 1**), and emphasize the correct handling of the endoscope to reduce the possible trauma.

Endoscopy_UCTN_Code_CPL_1AH_2AB

J. Sagar¹, V. A. Chavan², D. K. Shah³

- ¹ Department of Surgery, University College London and Royal Free Hospital, London, UK
- ² Glencairn Lodge Care Home, Fraserburgh, Aberdeenshire, UK
- ³ S.S.G. Hospital, Baroda, India

References

- 1 *Ajith C, Somesh G, Kumar B.* Iatrogenic swollen penis. *Sex Transm Infect* 2005; 81: 15–16
- 2 *Levy J, Lifshitz T.* Lidocaine hypersensitivity after subconjunctival injection. *Can J Ophthalmol* 2006; 41: 204–206
- 3 *Hayek G, Yazigi A, Jebara S et al.* Facial nerve paralysis during cervical plexus block for carotid artery endarterectomy. *J Cardiothorac Vasc Anesth* 2003; 17: 782–783
- 4 *Kimura H, Watanabe Y, Mizukoshi K et al.* Six cases of anesthesia mumps. *Nippon Jibiinkoka Gakkai Kaiho* 1993; 96: 1915–1921
- 5 *Katayama T, Katou F, Motegi K.* Unilateral parotid swelling after general anaesthesia. A case report. *J Craniomaxillofac Surg* 1990; 18: 229–232

Bibliography

DOI 10.1055/s-2007-966397

Endoscopy 2007; 39: E189

© Georg Thieme Verlag KG Stuttgart · New York · ISSN 0013-726X

Corresponding author

J. Sagar, MBBS, MS, MRCS

Department of Surgery, University College London and Royal Free Hospital

1 Ivy Walk

Rickmansworth Road

Northwood

Middlesex

HA6 2QQ

UK

jsagar_2001@yahoo.com