

Ileal pneumatosis

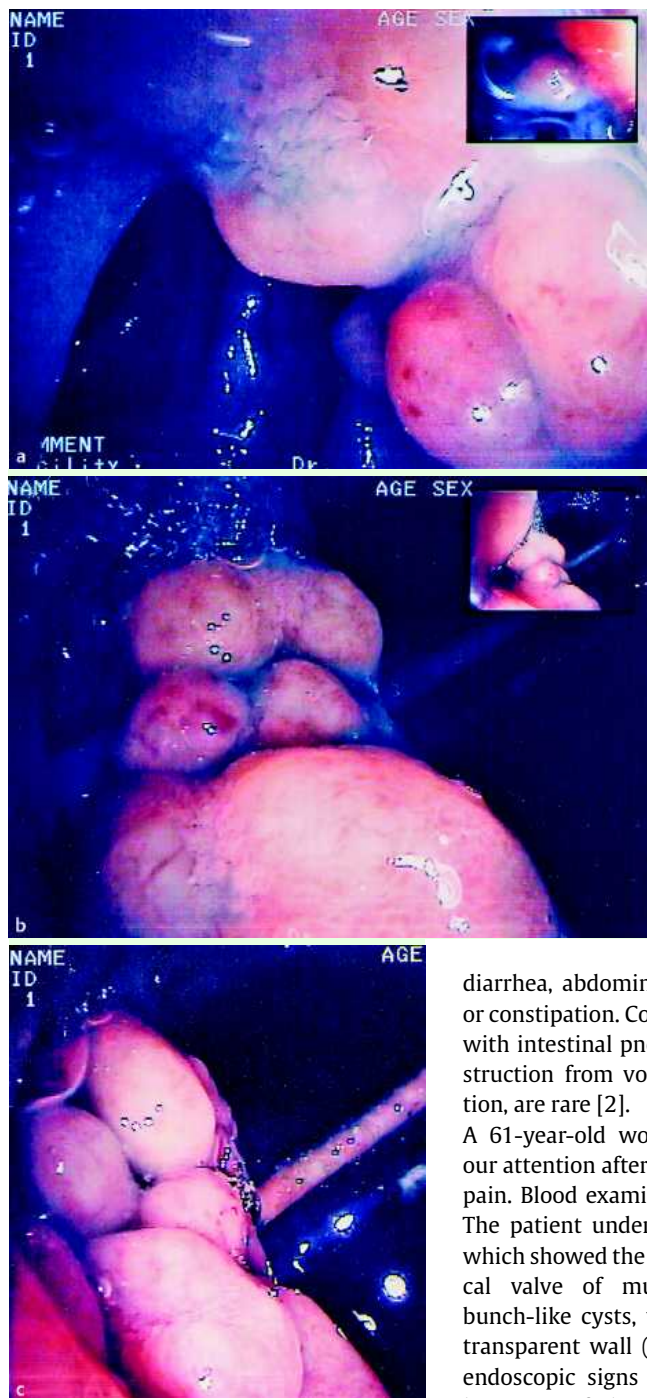


Figure 1 Ileal valve affected by pneumatosis.

Intestinal pneumatosis (IP) is a relatively rare, benign condition, described for the first time by Du Vernoi in 1730 [1]. It is characterized by the presence of gas inside the intestinal mucosa, and having an appearance of bunch-like cysts on endoscopy. Intestinal pneumatosis is usually asymptomatic, but may sometimes cause

diarrhea, abdominal discomfort or pain, or constipation. Complications associated with intestinal pneumatosis, such as obstruction from volvulus or intussusception, are rare [2].

A 61-year-old woman was referred for our attention after developing abdominal pain. Blood examinations were negative. The patient underwent ileocolonoscopy, which showed the presence on the ileocecal valve of mucosal and confluent bunch-like cysts, with a thin and semi-transparent wall (● **Figure 1**). The same endoscopic signs were observed in the last 5 cm of the ileum. A study of the 20 cm of ileal mucosa that were proximal to the 5 cm cystic length was negative. The patient also underwent ultrasonography and a computed tomography abdominal scan but no other kind of lesion was found.

Endoscopy_UCTN_Code_CCL_1AD_2AJ

E. Viale, B. Mangiavillano

Department of Gastroenterology & Gastrointestinal Endoscopy, IRCCS Vita-Salute San Raffaele University, San Raffaele Hospital Scientific Institute, Milan, Italy

References

- 1 Saito M, Tanikawa A, Nakasute K *et al*. Additive contribution of a multiple factors in the development of pneumatosis intestinalis: a case report and review of the literature. *Clin Rheumatol* 2006; 11: 1–3
- 2 St Peter SD, Abbas MA, Kelly KA *et al*. The spectrum of pneumatosis intestinalis. *Arch Surg* 2003; 138: 68–75

Bibliography

DOI 10.1055/s-2007-966488

Endoscopy 2008; 40: E212

© Georg Thieme Verlag KG Stuttgart · New York · ISSN 0013-726X

Corresponding author

E. Viale, MD

Vita-Salute San Raffaele University
IRCCS San Raffaele Hospital
Gastroenterology and
Gastrointestinal Endoscopy Unit
Via Olgettina 60
20132 Milan
Italy
Fax: +39-02-26432504
viale.edi@hsr.it