

Colonic involvement in pemphigus vulgaris: a rare cause of chronic diarrhea

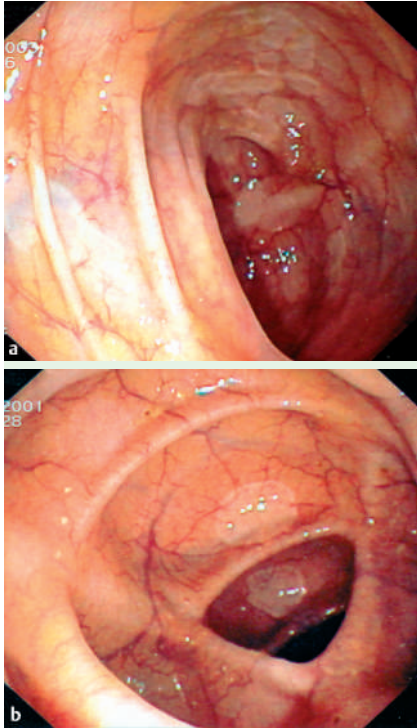


Figure 1 a, b Endoscopic appearance with multiple flattened, whitish bullous lesions disseminated throughout the colon.

Pemphigus vulgaris is an autoimmune disorder characterized by epithelial blistering affecting mostly the skin and oral mucosa. The gastrointestinal tract is rarely involved; when it is, localization is usually to the esophagus or rectum [1,2]. Colonic involvement is exceedingly rare, having been anecdotally described as the cause of hematochezia [3] or associated with ulcerative colitis [4]. Bullous colon lesions in a patient with bullous pemphigoid have also been described [5].

A 62-year-old white man was referred to our unit by the consultant nephrologists because of persistent diarrhea and hematochezia. The patient's past medical history included arterial hypertension, mild chronic obstructive pulmonary disease, and "minimal lesion nephropathy." Colonoscopy showed multiple bullous lesions throughout the colon (● **Figure 1**). Histologic analysis documented dissociation between epithelium and stroma with eosinophilic and lymphocellular infiltration of the lamina propria, around the basement membrane zone (● **Figure 2**). The diagnosis of pemphigus was confirmed

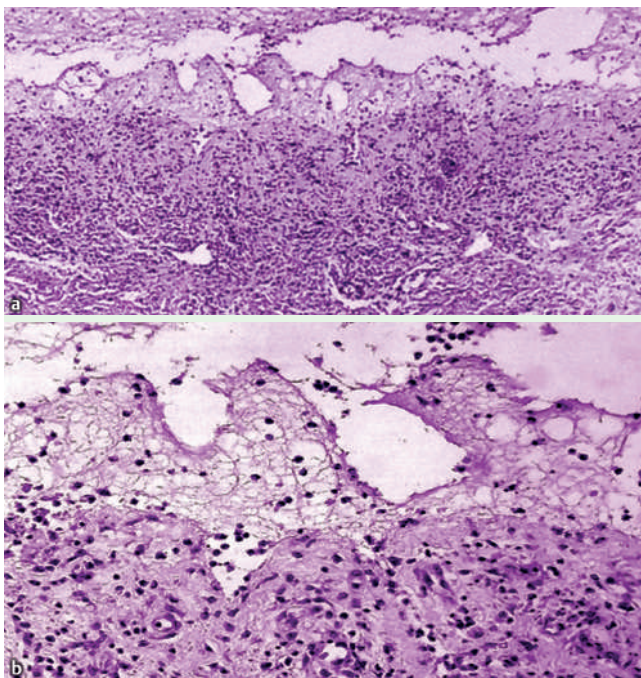


Figure 2 Histologic study revealed a supra-basilar acantholysis, eosinophilic infiltrate into the lamina propria and subepithelial bullae (H&E, × 20) with b dissociation of the epithelium from the stroma and sparse eosinophilic and lymphomonocytic infiltrate of the lamina propria (H&E, × 400).

with indirect immunofluorescence. Treatment with prednisone (1 mg/kg per day) and azathioprine (100 mg per day) was instituted with rapid clinical improvement. Complete remission of the symptoms was achieved in 6 weeks and the patient's condition since has been stable over a follow-up of almost 5 years. Immunofluorescence studies were repeated periodically and gave negative results. In the present case, gastrointestinal symptoms were the prevailing clinical picture, with lesions of the intestinal mucosa occurring long before those of the oral mucous membranes. The endoscopic pattern of scattered erythema, whitish flattened plaques, and flaccid bullae, and the clinical picture of persistent diarrhea, with or without rectal bleeding, should raise a suspicion of colonic involvement in pemphigus. Biopsies typically show acantholysis with inflammation of the submucosal tissues. The diagnosis is confirmed by means of indirect immunofluorescence studies and detection of IgG autoantibodies to *desmoglein 3* by enzyme-linked immunosorbent assay. Treatment is based on high-dose corticosteroids. Adjunctive therapy with immunosuppressive agents or intravenous immunoglobulins has proved successful and safe in steroid-resistant forms.

Endoscopy_UCTN_Code_CCL_1AD_2AD

G. Rotondano¹, L. Orsini¹, R. Marmo², M. A. Bianco¹, F. Cipolletta¹, R. Salerno³, C. Meucci¹, L. Cipolletta¹

¹ Division of Gastroenterology, Hospital "A. Maresca", Torre del Greco, Italy

² Division of Gastroenterology, Hospital "L. Curto", Polla, Italy

³ Division of Gastroenterology, Second University of Naples, School of Medicine, Naples, Italy

References

- 1 Gomi H, Akiyama M, Yakabi K, Nakamura T, Matsuo I. Oesophageal involvement in pemphigus vulgaris. *Lancet* 1999; 354: 1794
- 2 Stone DD. Rectal lesions and toxic dilatation of the colon in a case of pemphigus vulgaris. *Am J Dig Dis* 1977; 16: 163–166
- 3 Schwermann M, Lechner W, Elsner C, Kirchner T. Pemphigus vulgaris with involvement of duodenum and colon. *Z Hautkr* 1988; 63: 101–104
- 4 Kacar S, Sezgin O, Sahin T. Pemphigus vulgaris and ulcerative colitis [letter]. *Am J Gastroenterol* 2002; 97: 507–508
- 5 Sachsenberg-Studer EM, Runne U, Wehrmann T et al. Bullous colon lesions in a patient with bullous pemphigoid. *Gastrointest Endosc* 2001; 54: 104–108

Bibliography

DOI 10.1055/s-2007-966550
Endoscopy 2007; 39: E178–E179
© Georg Thieme Verlag KG Stuttgart · New York ·
ISSN 0013-726X

Corresponding author

G. Rotondano, MD
Via Cappella Vecchia 8
80121 Naples
Italy
gianluca.rotondano@virgilio.it