Intramural tracking in esophageal pseudodiverticulosis

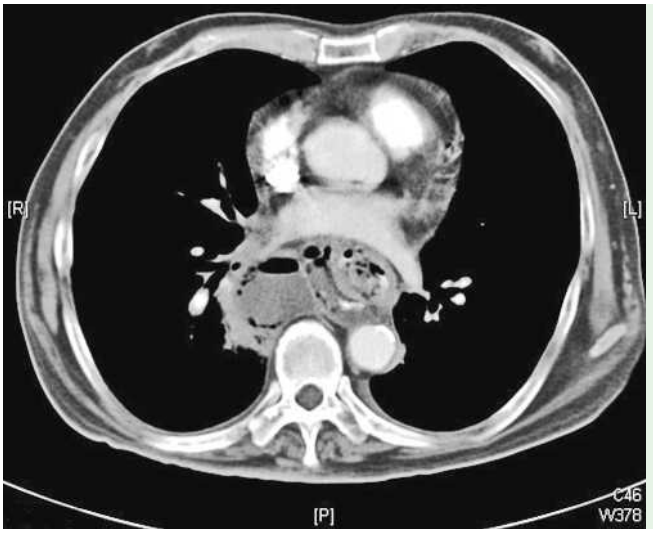

Fig. 1 Computed tomography (CT) of the thorax in July 2004 showing paraesophageal collections with fluid levels.

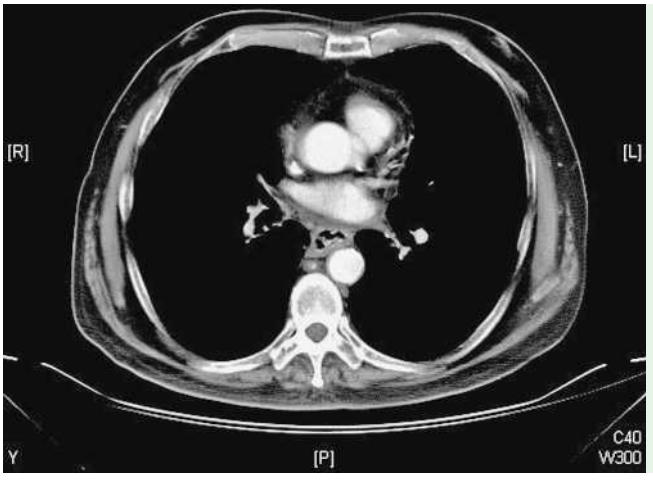

Fig. 2 CT thorax in June 2006 showing resolution of abscesses and paraesophageal collections, but with irregularity of esophageal mucosa.

Fig. 3 Barium esophagram in June 2006 showing intramural tracking sinuses running parallel to actual esophageal lumen.

Fig. 4 Endoscope looking back at the gastroesophageal junction, with opening of a sinus track next to it.

A 60-year-old man with diabetes mellitus and a long history of alcohol addiction presented with dysphagia and regurgitation of food. An initial endoscopy showed ulcerated lesions, which only yielded inflammatory cells on multiple biopsies, with no signs of malignancy. He subsequently developed a fever, and computed tomography (CT) of the thorax showed mediastinal abscesses and paraesophageal collections (▶ **Fig. 1**). Biopsies grew *Candida glabrata*, and cultures grew *Enterobacter* and *Klebsiella* species. The patient responded well to intravenous imipenem.

A repeat endoscopy post-recovery showed multiple ostia throughout his esophageal mucosa, which may have communicated with the abscesses, thus allowing self-drainage and contributing to the resolution of the infection. A CT thorax 2 years later showed resolution of the collections (▶ **Fig. 2**), with remnant irregularities of the esophageal wall. These were illustrated on a barium esophagram to be intramural sinuses dissecting the esophageal wall (▶ **Fig. 3**). These sinuses are likely to be ectatic changes of baseline esophageal intramural pseudodiverticulosis, due to chronic infection and inflammation. On endoscopy, some of these sinuses were seen to open into the gastric cardia (▶ **Fig. 4**).

Intramural tracking in esophageal intramural pseudodiverticulosis has been found to have a prevalence of up to 50% in patients with this rare condition, though not as florid as we have described [1]. The etiology of esophageal pseudodiverticulosis is unknown, but there have been suggestions of malignant potential [2]. As such, management of our patient includes frequent surveillance with endoscopy, keeping in mind the bizarre architecture of his esophagus and the possibility of malignancy within sinus tracts. The residual symptom of intermittent dysphagia can be treated symptomatically with dilatation during endoscopy [3].

Endoscopy_UCTN_Code_CCL_1AB_2AC_3AF

This document was downloaded for personal use only. Unauthorized distribution is strictly prohibited.

E. Wang[1], **A. Tang**[1], **S. Venkatesh**[2], **J. So**[1]
[1] Department of General Surgery, National University Hospital of Singapore, Singapore
[2] Department of Diagnostic Imaging, National University Hospital of Singapore, Singapore

References

1 *Canon CL, Levine MS, Cherukuri R et al.* Intramural tracking: a feature of esophageal intramural pseudodiverticulosis. Am J Roentgenol 2000; 175: 371 – 374
2 *Plavsic BM, Chen MYM, Gelfand DW et al.* Intramural pseudodiverticulosis of the esophagus detected on barium oesophograms: increased prevalence in patient with esophageal carcinoma. Am J Roentgenol 1995; 165: 1381 – 1385
3 *Teraishi F, Fujiwara T, Jikuhara A et al.* Esophageal intramural pseudodiverticulosis with esophageal strictures successfully treated with dilation therapy. 2006; 82: 1119 – 1121

Bibliography

DOI 10.1055/s-2007-966595
Endoscopy 2007; 39: E265 – E266
© Georg Thieme Verlag KG Stuttgart · New York ·
ISSN 0013-726X

Corresponding author

E. Wang, MD
Department of General Surgery,
National University Hospital of Singapore
5 Lower Kent Ridge Road
Singapore 119074
Fax: +65-67722418
etiennewang@gmail.com

This document was downloaded for personal use only. Unauthorized distribution is strictly prohibited.