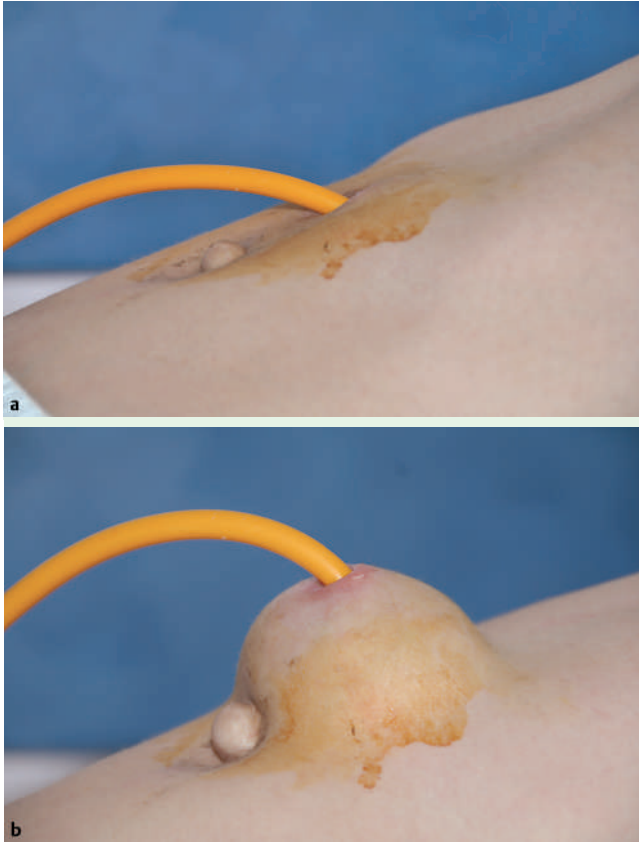


## Ventral abdominal herniation through PEG site in a child with cystic fibrosis



**Fig. 1** a Existing PEG site. b Abdominal bulging became prominent after an excessive cough.

An 8-year-old boy with cystic fibrosis was admitted to hospital because of recurrent respiratory infection. He was below the 5th percentile for weight, and the Pediatric Gastroenterology Department was consulted for nutritional support. A percutaneous endoscopic gastrostomy (PEG) tube was inserted by standard pull technique (Microvasive, 16F; Boston Scientific Corporation, Natick, Massachusetts, USA). After 4 months, the original gastrostomy tube was removed by traction and replaced by a button device. Two months later, the patient's parents noticed an abdominal bulging at the PEG site. Physical examination revealed a reducible bulge at the PEG site that became more prominent during cough, which was consistent with ventral hernia (● Fig. 1a,b).

There have been three previously reported cases of abdominal herniation through a PEG site in adults [1–3]. Chuang et al. reported a case of gastric wall herniation

through an existing PEG site caused by the PEG tube's exerting traction on the stomach [1]. Boldo-Roda et al. reported a case of abdominal herniation at a previous PEG site [2]. Kaplan et al. reported a woman who presented with Richter's hernia through a previous PEG site after heavy exercise [3]. Abdominal wall hernias occur at sites of weakness, most commonly at the umbilical area, the linea alba, or a previous incision – as in our case, a PEG site [4]. The most likely dynamic factor causing the herniation in our patient was increased intra-abdominal pressure due to chronic cough. In addition, placement of the PEG tube at the linea alba probably created a weakness in the abdominal wall. Traction on the PEG tube to replace it with a more ergonomic button device might have also separated the elements of the abdominal wall.

This is the first reported case of a child presenting with abdominal herniation

through a PEG site. Recommendations to prevent hernia formation at PEG sites include avoiding the linea alba, delaying removal of the PEG tube, avoiding excessive tension on the PEG tube, and having the patient avoid engaging in excessive exercise.

Endoscopy\_UCTN\_Code\_CPL\_1AH\_2AI

**O. Ozutemiz<sup>1</sup>, N. Oruc<sup>1</sup>, F. Tekin<sup>1</sup>,  
F. Ozgenc<sup>2</sup>, R. Yagci<sup>2</sup>**

<sup>1</sup> Gastroenterology Department, Ege University Faculty of Medicine, Izmir, Turkey

<sup>2</sup> Pediatric Gastroenterology Department, Ege University Faculty of Medicine, Izmir, Turkey

### References

- 1 Chuang CH, Chen CY. Gastric herniation through PEG site. *Gastrointest Endosc* 2003; 58: 416
- 2 Boldo-Roda E, Peris-Trias A, Perez de Lucia-Penalver G et al. Reflections in front of a case of ventral hernia after PEG tube removal. *Gastrointest Endosc* 2005; 62: 323–324
- 3 Kaplan R, Delegge M. An unusual case of a ventral Richter's hernia at the site of a previous PEG tube. *Dig Dis Sci* 2006; 51: 2389–2392
- 4 Park AE, Roth JS, Kavic SM. Abdominal wall hernia. *Curr Probl Surg* 2006; 43: 326–375

### Bibliography

DOI 10.1055/s-2007-966705

Endoscopy 2007; 39: E281

© Georg Thieme Verlag KG Stuttgart · New York · ISSN 0013-726X

### Corresponding author

**N. Oruc, MD**

Gastroenterology Department  
Ege University Faculty of Medicine  
Bornova  
Izmir  
35100  
Turkey  
Fax: +90-232-3427764  
nevintr@yahoo.com