Combined endoscopic ultrasound-guided choledochoduodenostomy and duodenal stent placement in a patient with pancreatic cancer

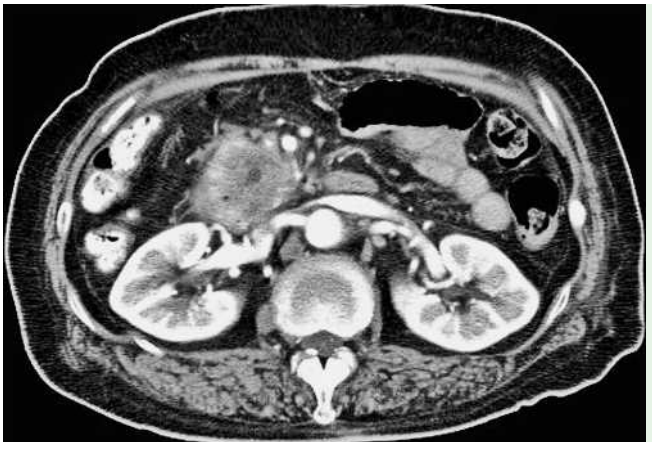

Fig. 1 Abdominal computed tomography showed a hypovascular mass in the head of the pancreas, with tumor invasion into the second portion of the duodenum.

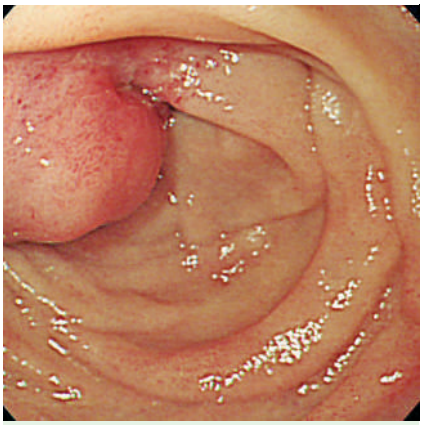

Fig. 2 Endoscopic examination also showed tumor invasion into the second portion of the duodenum.

Fig. 4 A biliary plastic stent was then inserted through the choledochoduodenostomy into the left hepatic bile duct.

Fig. 3 A duodenal self-expandable metallic stent was deployed in the duodenal stricture.

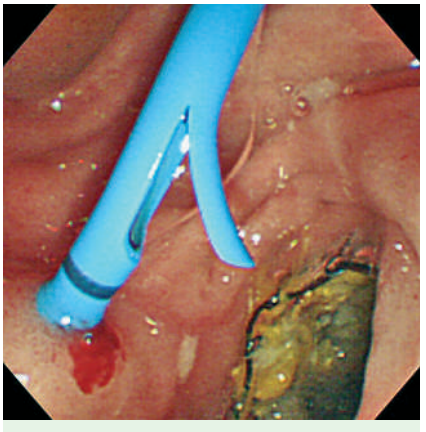

Fig. 5 One week after insertion, endoscopic examination showed that there was effective biliary drainage via the biliary plastic stent.

A 75-year-old woman was admitted to our hospital with obstructive jaundice. Abdominal computed tomography revealed a hypovascular mass in the head of the pancreas, dilatation of the bile ducts, and tumor invasion into the second portion of the duodenum (**Fig. 1**). Small nodules were also observed in the omentum, and a diagnosis of pancreatic cancer with peritonitis carcinomatosa was made. After percutaneous transhepatic biliary drainage (PTBD) was performed to relieve the jaundice, a duodenal self-expandable metallic stent was deployed in the duodenal stricture (**Fig. 2, 3**). Informed consent was obtained, and then a convex linear-array echo endoscope (GF-UCT2000; Olympus Co. Ltd., Tokyo, Japan) was used to puncture the dilated extrahepatic bile duct at the level of the duodenal bulb with an Olympus KD-10Q-1 needle-knife, using an electrosurgical generator (ICC200; ERBE, Tübingen, Germany). After the needle-knife was removed from the catheter, a guide wire was introduced into the bile duct under fluoroscopic guidance, and the catheter was removed. A 7-Fr biliary plastic stent (Flexima; Cook Endoscopy, Winston-Salem, North Carolina, USA) was then inserted into the left hepatic bile duct (**Fig. 4**). Once this procedure was complete, the PTBD catheter was removed (**Fig. 5**).

Endoscopic ultrasound-guided biliary drainage from the duodenal bulb has been reported recently [1–3]. If a patient has both a distal biliary stricture and a duodenal stricture around the major papilla, a biliary metallic stent can be deployed via the PTBD route. However, and particularly in patients with peritonitis carcinomatosa, recurrent cholangitis can occur because duodenal contents can reflux into the bile duct when a biliary metallic stent is deployed beyond the major papilla [4]. As a result, patients can require external biliary drainage. We suggest that endoscopic ultrasound-guided choledochoduodenostomy can be an effective treatment for patients who have a duodenal stent over the major papilla and peritonitis carcinomatosa.

Endoscopy_UCTN_Code_CPL_1AH_2AD
Endoscopy_UCTN_Code_CPL_1AL_2AD

This document was downloaded for personal use only. Unauthorized distribution is strictly prohibited.

R. Harada, H. Kawamoto, H. Fukatsu, K. Tsutsumi, M. Fujii, N. Kurihara, T. Ogawa, E. Ishida, Y. Okamoto, H. Okada, K. Sakaguchi

Department of Gastroenterology and Hepatology, Okayama University Graduate School of Medicine, Dentistry, and Pharmaceutical Sciences, Okayama, Japan

References

1 *Yamao K, Sawaki A, Takahashi K et al.* EUS-guided choledochoduodenostomy for palliative biliary drainage in case of papillary obstruction: report of 2 cases. Gastrointest Endosc 2006; 64: 663 – 667

2 *Giovannini M, Pesenti C, Bories E et al.* Interventional EUS: difficult pancreaticobiliary access. Endoscopy 2006; 38: 593 – 595

3 *Kahaleh M, Hernandez AJ, Tokar J et al.* Interventional EUS-guided cholangiography: evaluation of a technique in evolution. Gastrointest Endosc 2006; 64: 52 – 59

4 *Okamoto T, Fujioka S, Yanagisawa S et al.* Placement of a metallic stent across the main duodenal papilla may predispose to cholangitis. Gastrointest Endosc 2006; 63: 792 – 796

Bibliography

DOI 10.1055/s-2007-966707

Endoscopy 2007; 39: E284 – E285

© Georg Thieme Verlag KG Stuttgart · New York ·

ISSN 0013-726X

Corresponding author

H. Kawamoto, MD

Department of Gastroenterology and Hepatology
Okayama University Graduate School of Medicine, Dentistry, and Pharmaceutical Sciences
2-5-1 Shikata-cho
Okayama 700-8558
Japan
Fax: +81-86-223-5991
h-kawamo@md.okayama-u.ac.jp

This document was downloaded for personal use only. Unauthorized distribution is strictly prohibited.