

Single filiform polyp in asymptomatic healthy Korean without history of inflammatory bowel disease

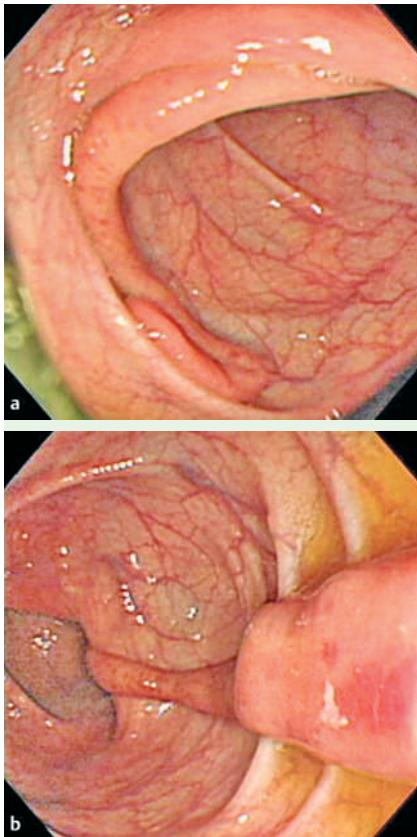


Fig. 1 Endoscopic appearance of the transverse colon. **a** A long, vermiform polyp was seen in the transverse colon. It was approximately 4.5 cm in the length and about 0.7 cm in diameter. **b** Mucosa was nearly normal except for focal erythema.

Here we report the first published case of a single filiform polyp discovered during routine screening in an individual without symptoms or a history of colonic disease. A 47-year-old man was transferred to our outpatient department for treatment of a single colon polyp which had been incidentally found on medical examination. Other results including upper endoscopy and laboratory test except colonoscopy were normal. The patient was asymptomatic and in good health. He had no significant history of intestinal complaint or gastrointestinal bleeding. We carried out a routine colonoscopic examination. Colonoscopy demonstrated a long, thin and finger-like polyp in the transverse colon

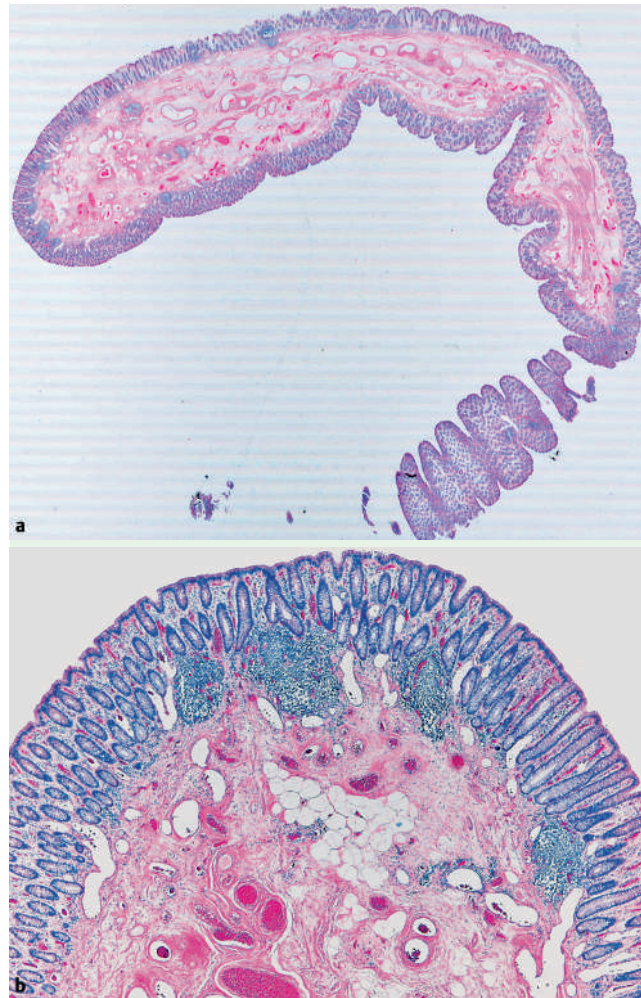


Fig. 2 Histologic views of the transverse colon (H & E). **a** A long slender appearance was shown (H & E, $\times 1$). **b** In submucosa, many stromal vessels with dilatation and congestion were found, as well as many adipocytes and mild fibrosis. Normal mucosa and lymphoid follicle below the mucosa were noted (H & E, $\times 40$).

(**Fig. 1a, b**). We carried out an endoscopic polypectomy by snare. Histologically, the polyp was filiform and covered by normal mucosa (**Fig. 2a, b**). Observation has continued to date, but no gastrointestinal symptoms or signs have been observed. Filiform polyposis is a rare condition of postinflammatory polyposis as a benign, nonspecific sequela characterized by multiple, slender, arborizing, vermiform projections of submucosa covered by mucosa on all sides. Filiform polyps are often long and thin (2–5 cm in length and 0.5 cm in diameter), and almost always multiple. Filiform polyposis has been rarely reported in patients without pre-

vious colonic disease. A review of the literature revealed only six cases of filiform polyposis without evidence and history of inflammatory bowel disease [1,2]. All of the patients experienced diarrhea or gastrointestinal bleeding. A single filiform polyp was shown in only two patients with severe hemorrhage [1,2]. To our knowledge, this is the first report of filiform polyposis, which was fortunately found in an asymptomatic adult without evidence of inflammatory bowel disease on health screening. Our case is the first that shows no symptoms and a single filiform polyp. It is difficult to explain why a filiform polyp is born in an asymptomatic adult.

Endoscopy_UCTN_Code_CCL_1AD_2AC

**H. M. Kang¹, Y. S. Kang¹, S. H. Kim¹,
J. K. Seong¹, B. S. Lee¹, H. Y. Jeong¹,
H. Y. Lee¹, K. S. Song²**

¹ Department of Internal Medicine, Chung Nam National University College of Medicine, Daejeon, Korea

² Department of Pathology, Chung Nam National University College of Medicine, Daejeon, Korea

References

- 1 Rozenbajgier C, Ruck P, Jenss H, Kaiserling E. Filiform polyposis: a case report describing clinical, morphological, and immunohistochemical findings. *Clin Investig* 1992; 70: 520–528
- 2 Macaigne G, Boivin JF, Cheaib S et al. Single filiform polyp revealed by severe hemorrhage in a patient with normal colon. Report of a case and review of the literature [abstract]. *Gastroenterol Clin Biol* 2006; 30: 913–915

Bibliography

DOI 10.1055/s-2007-966801

Endoscopy 2007; 39: E333–E334

© Georg Thieme Verlag KG Stuttgart · New York ·
ISSN 0013-726X

Corresponding author

H. Y. Jeong, MD

Department of Internal Medicine
Chung Nam National University
College of Medicine
Dae Sa Dong
640 Daejeon
South Korea
Fax: +82-42-254-4553
jeonghy@cnuh.co.kr